Aalen University

In fulfillment of the

Master's degree

(M.Sc.) Vision Science and Business (Optometry)

at the faculty of Aalen University, Germany

in cooperation with

New England College of Optometry, Boston, MA, USA,

and

Pacific University College of Optometry, Forest Grove, OR, USA

Developing a cataract handbook for optometrists

by

Sara Lončar

MASTER'S THESIS

Advisors:

Prof. Dr. Anna Nagl, Aalen University

Damjan Žunić, M.Sc., optometrist

August 2022

Abstract

Purpose: The purpose of this master thesis is to make a manual on cataracts so that optometrists in the Republic of Croatia have in one place everything about the causes, diagnosis, and treatment of cataracts. According to the World Health Organization cataract is one of the leading causes of vision impairment in the world. By properly diagnosing the type of cataract, we provide patients with a better quality of life and a visual aid with which they will achieve maximum visual acuity. This master's thesis will summarize all the knowledge from the master's degree in Aalen in order to get a broader picture of the formation of cataracts. On daily basis optometrists encounter cataract pathology, the goal is to better understand what affects cataract formation, from drugs to systemic diseases, and to ultimately help the client see better after resolving cataract pathology.

Methods: Secondary quantitative research that includes randomized controlled trials, studies, and case-controlled studies from public records, journals, and government publications available on PubMed and other science journal literature.

Results: the result is a manual that contains all the relevant information about cataracts in one place that optometrists need for their daily work.

Conclusions: Cataracts are abnormalities in the lens of the eye that cause a loss of transparency. One of the most commonly used methods for cataract surgery involves ultrasound, using the phacoemulsification method with a small surgical incision of 3 mm and implantation of an artificial intraocular lens through small openings. Today's tendency is that removing cataracts results in a reduction of operative and postoperative complications, faster rehabilitation vision, and greater patient satisfaction. Today, multifocal intraocular lenses are available in addition to removing cataracts, they also correct presbyopia, and aspheric intraocular lenses prevent unpleasant spherical aberration. The development of cataract surgery is accompanied by new technological achievements in sophisticated phacoemulsification devices, as well as the design of intraocular lenses. So today we have intraocular lenses with a blue filter to protect the macula or toric intraocular lenses for simultaneous correction of astigmatism and aphakia.

Keywords: anatomy, cataract, intraocular lenses, surgery, optometry, congenital cataract, systemic disease

Table of contents

List of Figures

List of Abbreviations

NC	Nuclear cataract
COR	Cortical cataract
PSC	Posterior subcapsular cataract
LOCS III.	Lens opacity classification system III.
WHO	World health organization
FDA	Food and drugs administration
IOT	Intraocular pressure
IOL	Intraocular lens
AL	Axial length
ACD	Anterior chamber depth
LT	Lens thickness
CCT	Central corneal thickness
OCT	Optical coherence tomography
PCO	Posterior capsular opacity
PS	Pupil size
D	Diopter
PMMA	Polymethyl methacrylate
YAG laser	Yttrium aluminum garnet
UV	Ultraviolet
EDOF	Extended Depth of Focus
ICCE	Intracapsular cataract extraction
ECCE	Extracapsular Cataract Extraction
PHACO	Phacoemulsification
FLACS	Femto laser assisted cataract surgery
CME	Cystoid macular edema
TASS	Toxic anterior segment syndrome

1 Lens embryology

The development of the eye begins in the germinal period, between week 3 and week 10 when the outer cell layer of the zygote becomes the placenta and while the inner layer of cells forms three basic divisions in the organism: ectoderm, mesoderm, and endoderm. Mesodermal and ectodermal cells form tissues that contribute to eye formation. Neural tube ectoderm gives rise to the retina, iris, and ciliary body epithelia, optic nerve head, smooth iris muscles, and vitreous humor. Eyelids, lacrimal apparatus, conjunctival and corneal epithelial, and lens rise from surface ectoderm, while other ocular structures form from mesenchyme. By the end of the germinal period, on the 21st day, a neural tube is formed. During the embryonic period between 4 and 8 weeks of pregnancy all major internal and external organs, including the eyes, develop and form. At the beginning of 4th week of development, two small optic pouches are formed on each side of the forebrain in the neural folds. By closing the anterior end of the neural tube, these pouches form protrusions of the forebrain and become out pocketing called optic vesicles (*lat. Vesicula ophthalmic*). By the 5th and 6th week of development, optic vesicles grow through the ectoderm and form an optic fissure (*lat. cupula optica*), which later will become the optic cup. The optic fissure is connected with the forebrain through the optic stalk. By the end of the formation of the optic fissure, the posterior pole of the lens is placed in the recess of the optic fissure. The cells of the surface ectoderm overlying the optic vesicles become columnar. That area of thickened cells is called a lens plate or lens placode. By the 33rd day of embryonic period invagination, the lens pit continues developing and results in a single layer of cells encased within a basement membrane (later lens capsule) called lens vesicle. (1) Cells on the posterior pole of that sphere elongate and migrate, first making primary lens fibers and constituting the embryonic nucleus. They can wrap around the lens, pole to pole. By 7 weeks of pregnancy, anterior cells migrate toward the equator and become secondary lens fibers, and form lens epithelium. Later fibers (secondary lens fibers) cannot reach all the way around and therefore sutures develop. First sutures are seen with the fetal lens and they form 'Y sutures'. These sutures present a meeting of embryonal and fetal nuclei. Experimental eye research shows that the majority of crystalline lenses are characterized by sutures, basic 'Y sutures' of mice, cats, dogs, cows, sheep, rats, and guinea pigs show that lenses develop and grow like line sutures with additional complexity. (2) These 'Y' fibers grow in shells with three straight fibers which are extended to the anterior pole but too short to extend to the posterior pole and three straight fibers which are extended to the posterior pole but too short to reach the anterior pole. Because of that, the remaining fibers are positioned between the straight fibers and grow on opposite ends, they overlap and form three anterior and posterior sutures oriented at 120° to one another. (3)

Figure 1. Development of the eye structures

Period after conception	Event
22nd day	Optic groove appears
25th day	Optic vesicle forms from optic pit
26th day	Primordia of superior rectus, inferior rectus, medial rectus, and inferior oblique appear
27th day	Formation of lens plate from surface ectoderm Primordium of lateral rectus appears
28th day	Embryonic fissure forms Cells destined to become retinal pigment epithelium acquire pigmentation
29th day	Primordium of superior oblique appears
5th week	Lens pit forms and deepens into lens vesicle Hyaloid vessels develop Primary vitreous develops Osseous structures of the orbit begin to develop
6th week	Closure of embryonic fissure Corneal epithelial cells develop interconnections Differentiation of retinal pigment epithelium Proliferation of neural retinal cells Formation of secondary vitreous Formation of primary lens fibers Development of periocular vasculature Appearance of eyelid folds and nasolacrimal duct Ciliary ganglion appears
7th week	Migration of ganglion cells toward optic disc Formation of embryonic lens nucleus Development of choroidal vessels from periocular mesenchyme Three waves of neural crest migration: first wave: formation of corneal and trabecular endothelium second wave: formation of corneal stroma third wave: formation of iris stroma Formation of tunica vasculosa lentis Sclera begins to form
3rd month	Differentiation of precursors of rods and cones Ciliary body develops Appearance of limbus Anterior chamber appears as a potential space Sclera condenses Eyelid folds lengthen and fuse
4th month	Formation of retinal vasculature begins Beginning of regression of hyaloid vessels Formation of physiologic cup of optic disc Formation of lamina cribrosa Major arterial circle of iris forms Development of iris sphincter muscle Development of longitudinal ciliary muscle and processes of ciliary body Formation of tertiary vitreous Bowman's membrane forms Canal of Schlemm appears Eyelid glands and cilia form
5th month	Photoreceptors differentiate Eyelid separation begins
6th month	Cones differentiate Ganglion cells thicken in macula Differentiation of dilator pupillae muscle Nasolacrimal system becomes patent
7th month	Rods differentiate Ora serrata forms Migration of ganglion cells to form nerve fiber layer of Henle Choroid becomes pigmented Circular ciliary muscle fibers develop Myelination of optic nerve Posterior movement of anterior chamber angle Orbicularis muscle differentiation
8th month	Completion of anterior chamber angle formation Hyaloid vessels disappear
9th month	Retinal vessels reach the temporal periphery Pupillary membrane disappears
After birth	Development of macula

Source 1.https://entokey.com/embryology-pathology/ 25.06.2022.

Figure 2.Development of vertebrate eye

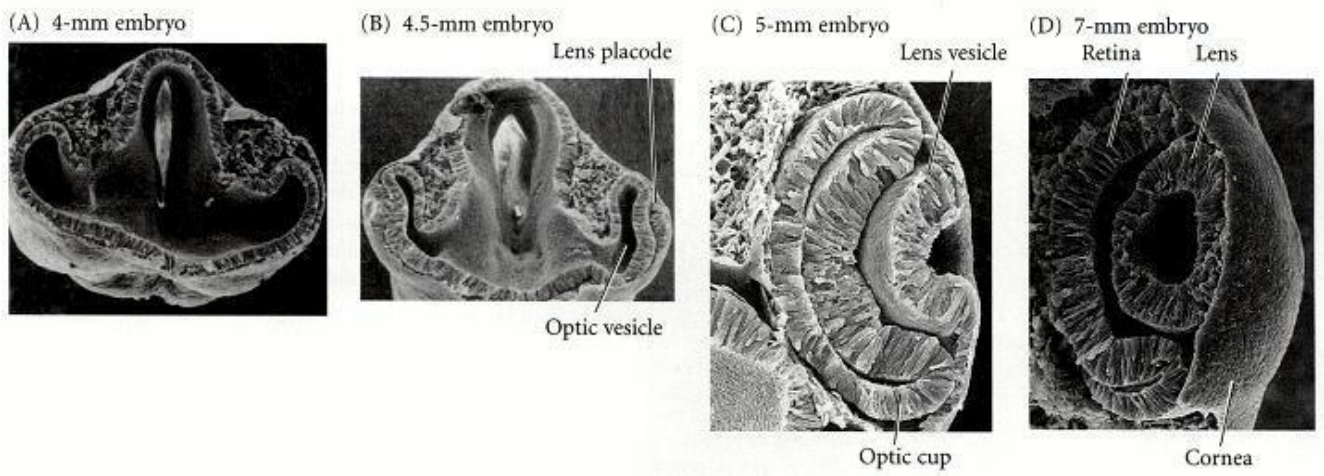

Source 2.https://www.ncbi.nlm.nih.gov/books/NBK10024/figure/A2922/?report=objectonly 25.06.2022

Figure 3. Development of lens fibers

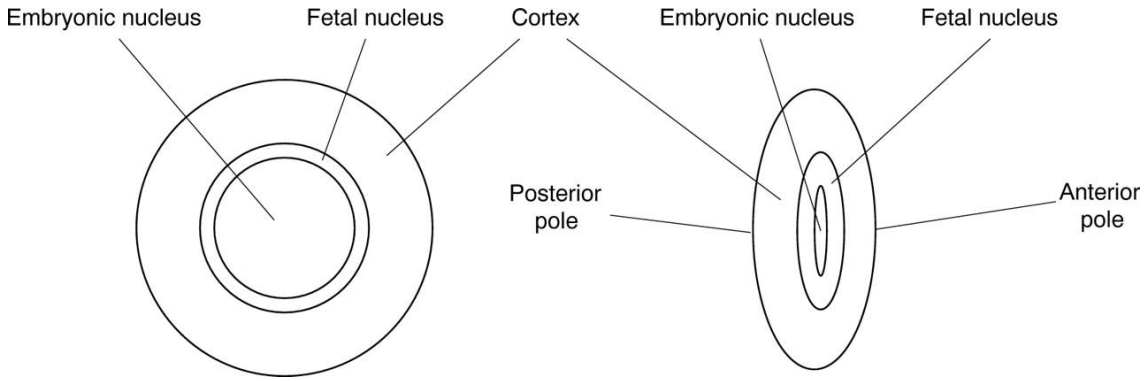

Source 3. https://medicoapps.org/m-anatomy-physiology-of-lens/ 25.06.2022.

1.1 Hyaloid system and vitreous remnants

Between the posterior pole of the lens and optic fissure is where the vitreous develops. The vitreous *(lat. corpus vitreum)* is a clear tissue that fills the inner cavity of the globe, it's composed of 98-99,7% of water and also contains fibers of vitrosin [1]hyaluronic acid which is secreted by hyalocytes. [2]One of the functions of the vitreous is to help keep the retina in place and absorb shock waves from the saccadic eye movements. The collagen fibers form a complex network to provide attachment to the adjacent structures including the posterior lens capsule, ciliary body epithelium, internal limiting membrane of the retina, and optic nerve head. (4)

The vitreous development occurs in two stages in the fetus, primary vitreous begins to form at 3 and 4 weeks of development and it is a dense, vascular tissue. (5) During this period the hyaloid artery connects the optic nerve head to the lens, creating a dense network around the lens and anastomoses with the blood supply that makes the layer called tunica vasculosa lentis. (6) That vascular mesenchymal layer divide in two membranes, posterior pupillary membrane that covers posterior surface of the lens and anterior pupillary membrane that covers anterior pole of the lens. After the 6th week of gestation, secondary vitreous starts forming, and the hyaloid artery is fully developed. The secondary vitreous is a clear tissue and is secreted by developing retinal cells and it fills the globe. To resolve the primary vitreous, the secondary vitreous compresses the primary vitreous into a tube from the optic nerve head to the lens and permits a passage from the lens to the retina. The hyaloid artery begins to atrophy by the 7th month of fetal development and it closes first at the optic nerve head. By birth, the hyaloid system has to be degenerated and absorbed. The atrophy and degeneration of the hyaloid system do not always occur in a complete process and some remnants are left behind.

Figure 4. Developing of the hyaloid artery

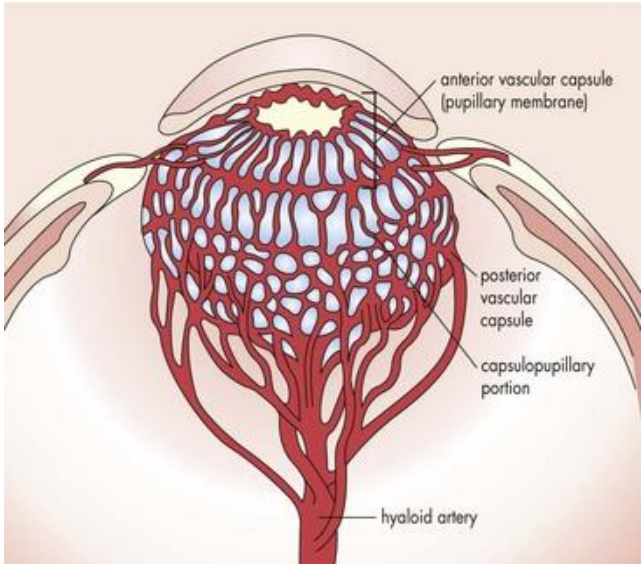

Source 4. https://entokey.com/embryology-pathology/ 25.06.2022.

If remants are left from the anterior pupillary membrane we can se on anterior lens capsule, and can be present as persistent pupillary membrane or epicapsular star. Persistent pupillary membrane appears as strands of tissue bridging the pupillary area. In some cases, membrane can obscure the pupil and cause amblyopia. Some research show that intrauterine stress especially from chronic hypertension can accelerate the disappearance of that membrane.(7)

[1] Vitrosin- an insoluble form of collagen, distributed through the vitreous as very fine fibrils
[2] Hyalocyte- cells in the vitreous body that produce hyaluronic acid and collagen

Figure 5. Persistent pupillary membrane

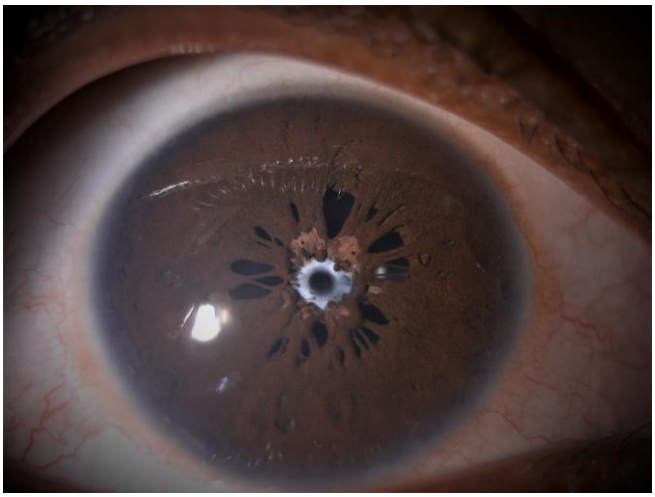

Source 5.https://eyewiki.aao.org/Persistent_Pupillary_Membrane#cite_note-hadi3-3 25.06.2022.

Epicapsular stars present as multiple, star-shaped brown-pigmented opacities in the central anterior lens capsule, they are not dense and have no effect on the visual function.

Figure 6. Epicapsular star

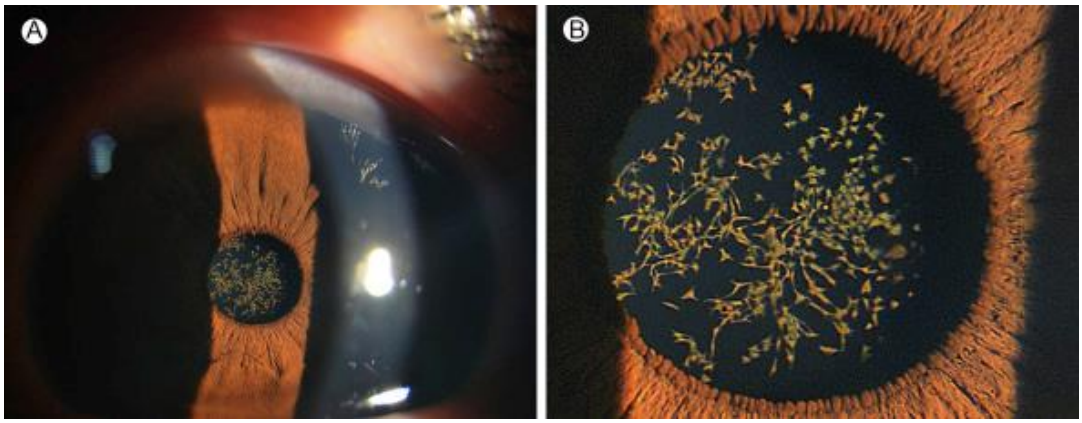

Source 6. https://els-jbs-prod-cdn.jbs.elsevierhealth.com/cms/attachment/73bfa938-e07d-44e3-9541-0ac15d1812f7/gr1.jpg 25.06.2022.

If remnants are left on the posterior capsule and occur as small white opacity, nasal to the central visual axis, that is called Mittendorf's dot. A small remnant of hyaloid artery extending from the ONH occurs sporadically and is found in approximately 2% of the population. It may represent a very mild form of PHPV (Persistent hyperplastic primary vitreous), but is not progressive and does not interfere with the vision it can occur unilateral or bilateral. Clinically appears white in direct illumination examination by slit lamp or black/grey in retro illumination by ophthalmoscope. (8)

Figure 7. Mittendorf's dot

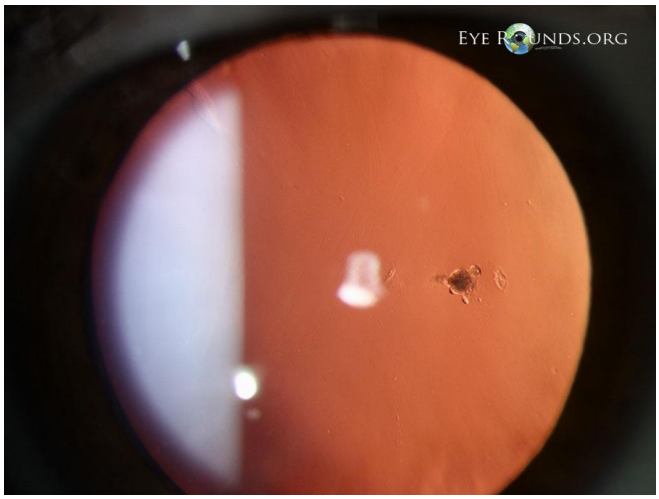

Source 7. https://webeye.ophth.uiowa.edu/eyeforum/atlas/pages/mittendorf-dots.htm 25.06.2022.

Figure 8. Hyaloid artery in infant

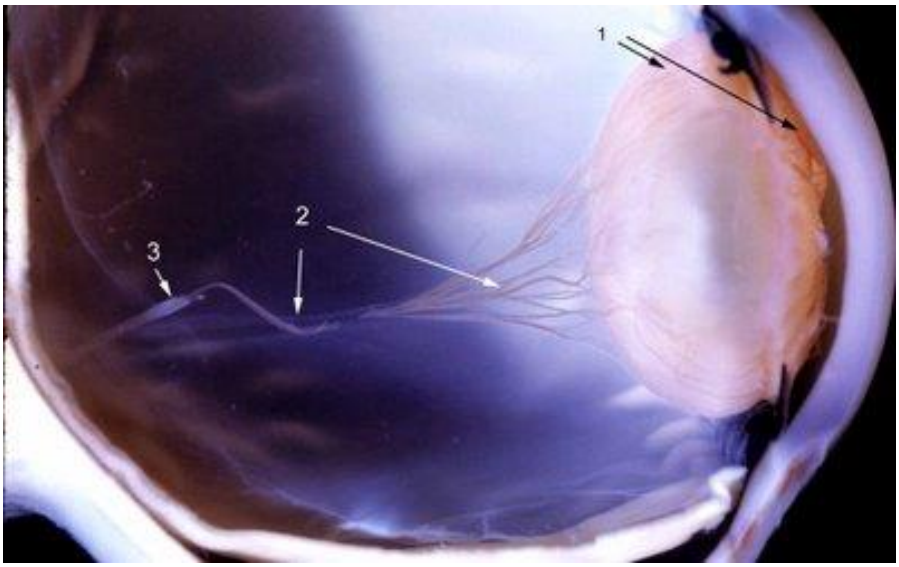

Source 8. http://www.missionforvisionusa.org/2007/07/mittendorfs-dot.html 25.06.2022.

Figure 7 shows a hyaloid vascular system in a premature infant. Arrow 1 shows tunica vasculosa lentis, which surrounds the lens and borders with the hyaloid vascular system, where arrow 2 is pointing. Arrow 3 shows the glial sheath of the hyaloid artery.

Persistent hyperplastic primary vitreous (PHPV) is a condition where the primary vitreous and hyaloid systems fail to atrophy and regress. It is a unilateral, rare condition and is not associated with premature birth. PHPV can be classified into two types, anterior and posterior. Similar in both types are microcornea and strabismus. In the anterior type of PHPV mass and membranes create traction which may pull the ciliary processes inward and can catch the edge of the lens. Because of that traction on the ciliary body, aqueous humor production can be affected and result in lower or higher IOP because of the shallow anterior chamber. In the posterior type of PHPV, we can see vitreous membranes and vitreoretinal adhesion, peripapillary RPE changes, retinal folds, and hypoplastic optic nerve. Posterior PHPV occurs when the remnant vascular stalk is seen arising off the optic

nerve but does not reach the lens. (9,10) Before diagnosing PHPV we need to exclude other conditions which can present with strabismus and leukocoria[3], such as retinoblastoma. (11)

Figure 9. Leukocoria on the left eye

Source 9. https://healthjade.net/leukocoria/ 25.06.2022.

Figure 10.Magnetic resonance imaging shows a hyaloid artery proliferation posterior to the lens and vitreous hemorrhage on the right eye

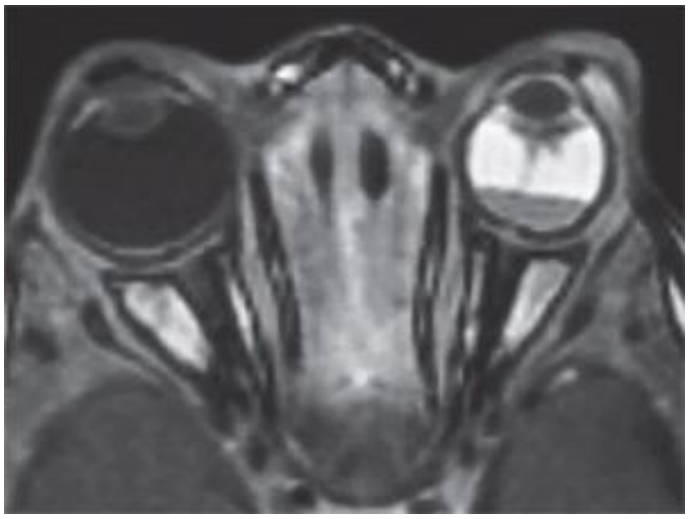

Source 10.https://www.reviewofophthalmology.com/article/how-to-treat-persistent-fetal-vasculature 25.06.2022.

Research by Brown (1960) has shown that the entire length of the hyaloid artery can be seen in a 28-week baby and remnants can be seen posteriorly in 32 weeks old baby. That remnant disappears by the 38th week of life. Another research by Roper-Hall (1960) has shown the connection between babies' weight and remnants of a hyaloid artery. 90% of infants with a weight between 2 and 3 lb at birth (0,907 kg and 1,36 kg) have shown complete remnants of the hyaloid artery and in 58% of infants between 3 and 4 lb (1,36kg and 1,81 kg) remnants were seen. (6)

Other remnants of hyaloid vasculature can be seen on the optic nerve, peripapillary or congenital vascular loops are twisted arterial vessels that are extended in the vitreous from ONH. Loops have a smooth, uniform, and twisted shape. They do not affect the vision or cause a problem because they do not leak and that is the difference between neovascularization and optociliary shunts.

[3] Leukocoria- the white pupil, can be a sign of congenital malformation

Figure 11. Peripapillary loop on the ONH

Source 11. https://entokey.com/congenital-abnormalities-of-the-optic-disk/ 25.06.2022.

Bergmeister's papilla is a hazy white remnant, we can see clinically on nasal side of the ONH. It is composed of glial tissue. It is benign condition and it can be associated with microphthalmia, cataract, persistence of primitive vitreous, tractional detachment or macular hole.(12)

Figure 12. Bergmaister's papillae

Source 12. https://imagebank.asrs.org/file/5360/bergmeister-papillae 25.06.2022.

2 Lens anatomy

Lens is biconvex, encapsulated, transparent, crystalline and avascular structure placed between posterior surface of the iris and the vitreous in shaped depression called patellar fossa. After fetal development all blood supply or innervation stops in the lens. Weight of the lens at birth is 65mg and at the extreme of the age 258 mg. It is an important component of the optical system of the eye, it allows the light to the retina, provides accommodation and maintain own clarity. Structure of the lens is made from lens capsule, lens epithelium, lens fibers, nucleus and cortex. Lens capsule is transparent, collagen membrane which surrounds lens completely. Does not contain any elastic tissue and is thickest basement membrane of the body. It is permeable to water and ions and offers a barrier to large protein molecules. Ciliary zonules hold the lens in position and enable the ciliary muscle to act on the lens, they run from ciliary body and fuse into lens capsule around equator region. They originates from the non pigmented epithelium of ciliary body. During age related loss of accommodation result from change in capsular elasticity which is due to loss of lamellar pattern.

All metabolic and transport process of the lens occur in the anterior lens epithelium, which is a single layer of cuboidal nucleated cells which lies deep in anterior capsule of the lens. In lens epithelium occurs regulation of the lens electrolyte balance to maintain normal hydration, accommodation and protection from oxidative damage. Throughout life this cells dividing and elongate forming new lens fibers. This lens fibers form bulk of the lens and laid on the older deeper fibers, that initial fibers forming fetal nucleus and appears in Y-shaped sutures. Anteriorly this Y-sutures we can see in upright and posteriorly inverted Y. (13)

Figure 13. Lens structure

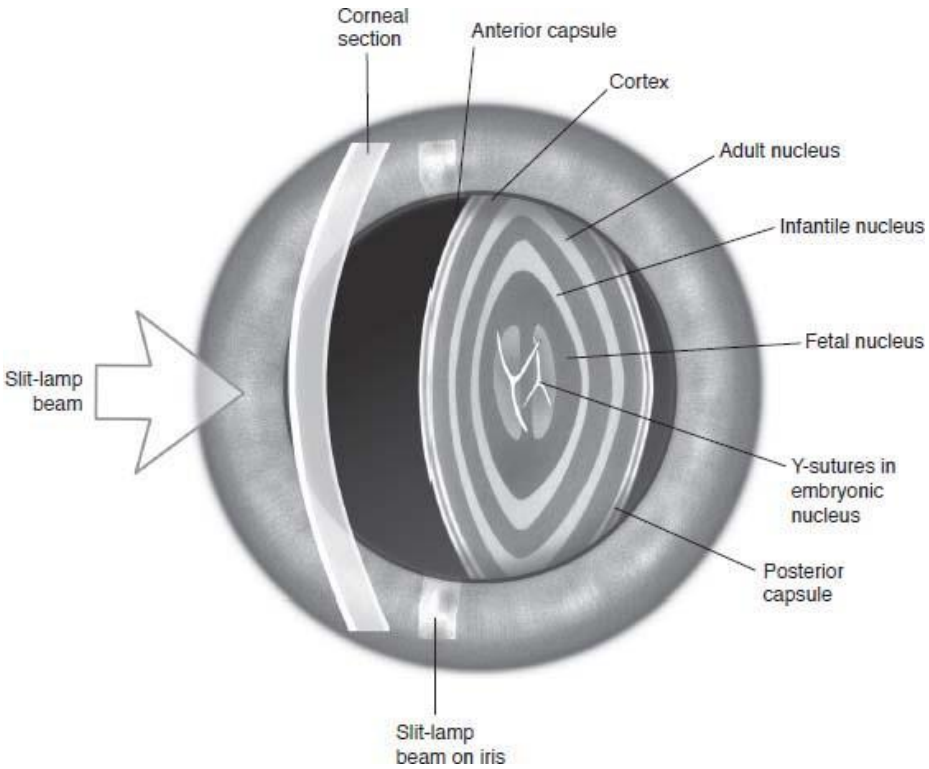

Source 13. https://www.aao.org/image.axd?id=d99265d7-9e70-43c3-ab9d-b5ba8cd29036&t=637442516457683189 25.06.2022.

Figure 14. Y-sutures

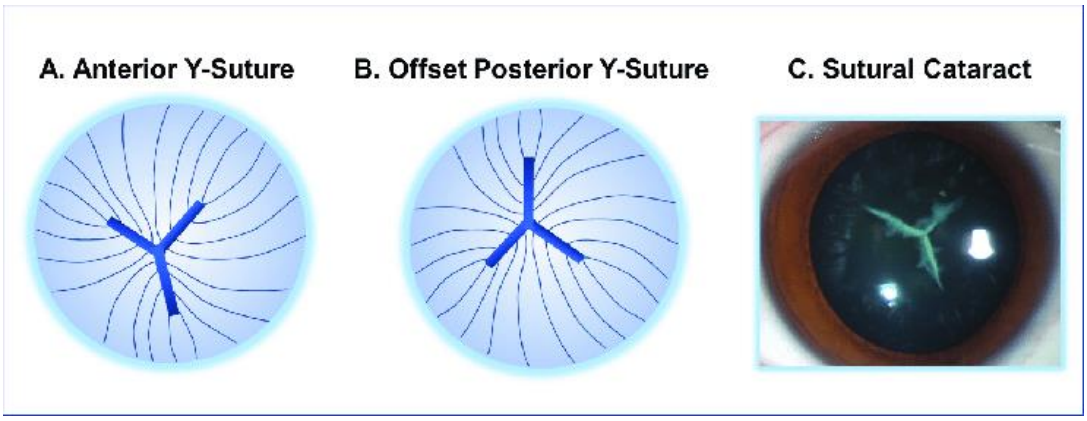

Source 14. https://www.researchgate.net/publication/345209343/figure/fig5/AS:983474446028804@1611489988615/Anterior-Y-suture-and-offset-posterior-Y-suture-in-humans-A-The-anterior-ends-of-lens.png 25.06.2022.

Nucleus of the lens are formed from the earliest lens fibers in the center and all later fibers form cortex of the lens. It is divided into embryonic nucleus, fetal nucleus, infantile nucleus and adult nucleus. Formation of the fetal nucleus which is encloses to the embryonic nucleus is complete at the birth. Infantile nucleus continuous formatting through-out the life from fiber which starts at the equator during first and second decades of life. Adult nucleus are formed during third decade. (14) Most peripheral part of the lens nucleus which lies outside the adult nucleus is lens cortex and has the youngest lens fibers.

Figure 15. Nucleus of the lens

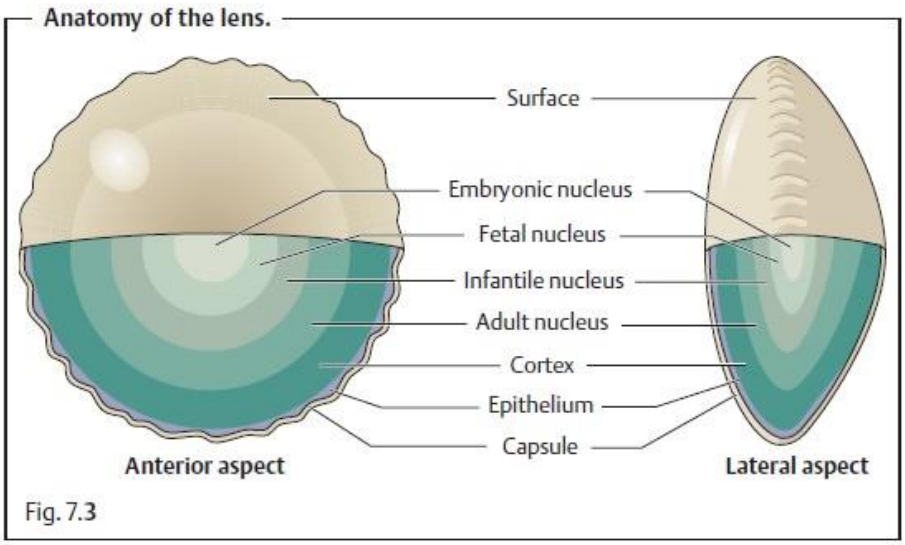

Source 15.https://www.brainkart.com/article/Eye-Lens--Basic-Knowledge_26018/ 25.06.2022.

2.1 Biochemistry and physiology of the lens

Lens contains 65% of water, 34% of protein and 1% of lipid, carbohydrate, ascorbic acid and glutathione. Low amount of the water maintains the refractive index of the lens. During the development, lens fibers loss their nuclei and the cytoplasmic organelles become specialized for the production of the lens protein- crystallin. Proteins in the lens have two major groups ; water soluble proteins (which contains alpha, beta and gamma crystalline) and water insoluble proteins(this proteins are soluble in the urea). Proteins helps in change of shape during cell differentiation and provide the lens with stress-resistant and oxidative properties. Crystalline constitute almost 60% of lens fiber mass which is the highest protein concentration in the body. Reason why some part of the lens has the different refractive index is because of different concentration of the crystalline in the lens. If concentration were uniform throughout of the lens, spherical and chromatic aberrations would not be compensating. During age, lens soluble proteins gradually convert into insoluble albuminoids[4] which increase opacity of the lens and become cataract. Carbohydrate in the lens especially glucose is main source of the energy for active transport of ions and amino acids, for maintenance of the transparency and synthesis of protein. That energy is produced in the anterior lens epithelium where is major site of the active transport. Lipids (cholesterol) in the lens constitutes lens cell membrane and are associated with cell division in anterior lens epithelium. Main source of nutrient supply lens takes from aqueous humor which is main source and vitreous humor by diffusion. Protection of oxidative damage in the lens is produced by glutathione, a tripeptide[5] which we can find in epithelial layer. (15)

Figure 16. Energy transport mechanism through the lens

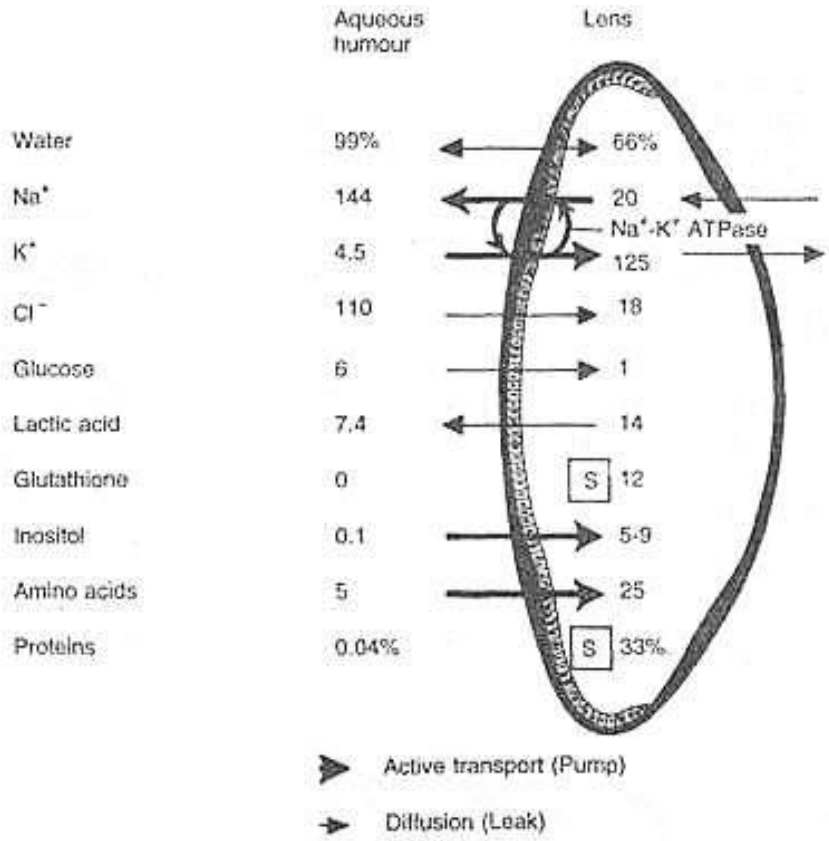

Source 16.http://www.oculist.net/downaton502/prof/ebook/duanes/pages/v8/v8c010.html 25.06.2022

[4] Albuminoid- class of simple proteins as keratin, gelatin or collagen that are insoluble in neutral solvents
[5] Tripeptide-peptide derived from three amino acide joined by two or three peptide bonds

2.1.1 Developmental anomalies of the lens

Abnormalities of the lens can be seen in systemic and ocular congenital malformations or diseases. That malformations can lead to the reduced visual acuity or amblyopia if are not detected in early age. Some genetic disorders like Alport syndrome[6], can manifest with a lenticonus, corneal opacities, cataracts and retinopathies. Because of defect on genes which provide instructions for IV collagen, creates conical protrusion of the lens surface into the anterior chamber. During slit-lamp examination we can see distinctive 'oil droplet'appearance. It creates lens curvature more convex centrally and rarely can caused rupture of the capsule. With age, the bulge progressively increases in size and can caused opacites in the lens cortex. This condition is usually bilateral.(16)

Figure 17. Lenticonus

Source 17.https://www.atlasophthalmology.net/photo.jsf;jsessionid=6933432BC0CBAF660200FA8053E21CE1?node=3837&locale=pt 05.07.2022.

Similar condition is lentiglobus, very rare and usually unilateral condition. Present with hemispherical deformity of the posterior surface of the lens, often associated with posterior polar lens opacity.

Lens coloboma is presented as flattening of the lens rim in the area of absence of zonular fibers. Cause of this condition is faulty development of the zonule. The lens may be smaller, thicker and more spherical. In research Hovland reported several cases of bilateral retinal detachment associated with lens coloboma. In that cases lens coloboma was in the same quadrant as retinal detachment. That detachments were secondary to the giant retinal breaks. Research shows that the origin of that anomaly might be related to embryological development, and causes synechia between peripheral optic cup and the lens causing vitro-retinal traction and produce retinal tears.(17)

[6] Alport syndrome- genetic condition caused by mutations on genes who provide instructions for making component of a IV collagen, characterized by kidney disease, hearing loss, and eye abnormalities

Figure 18. Lens coloboma

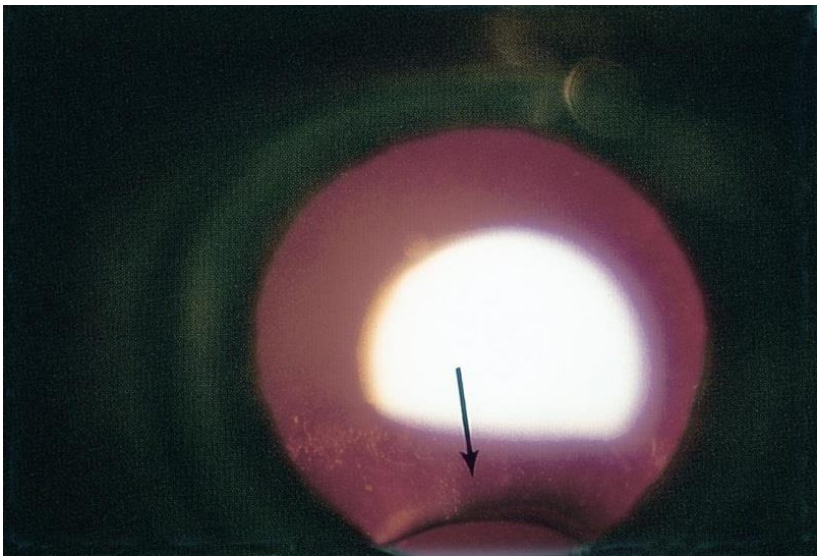

Source 18.https://eyewiki.aao.org/File:Coloboma_of_lens.jpg 05.07.2022.

Lowe's syndrome[7] and Will-Marchesani syndrome[8] can caused microspherophakia. Condition where lens is reduced in equatorial diameter and have increased lens thickness, a rare condition usually bilateral. Research shows that almost 51% of patients has reported glaucoma, which can be caused by pupillary block mechanism or anterior synechiae. This condition might lead to lens dislocation or subluxation while zonular instability. (18,19)

Figure 19. Microspehrophakia and subluxation of the lens

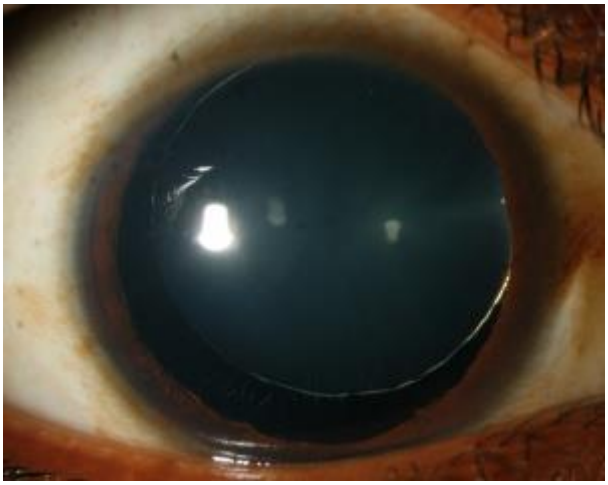

Source 19. https://eyewiki.aao.org/w/images/1/thumb/d/de/218241_0.665898001525083162.jpg/450px-218241_0.665898001525083162.jpg 05.07.2022.

[7] Lowe's syndrome- rare oculocerebrorenal disorder characterized by multiple features manifestations include menal retardation, hypotonia, kidney dysfuncton and can manifest ocular with congenital cataracts, keloids on cornea and glaucoma.

[8] Weill-Marchesani syndrome-inherited connective tissue disorder charterized by abnormalities of the lens, secondary glaucoma, cardiovascular defects and brachydactyly

Instability of zonular fibers can lead to the condition where zonulles breaks and leave the lens to free floats in the vitreous or can be partially displaced within the lens place. That condition called dislocated lens or subluxated lens. It may occur after trauma or can be associated with other disease or genetic syndromes, this condition can cause complications liked pupillary block glaucoma, retinal damage and refractive shifts. Marfan's syndrome[9] and Ehler -Danlos syndrome[10] are rare genetic disorder where we can find these conditions. Both of this syndrome affects connective tissue in the body caused by genetic mutations in proteins called collagen. These mutations change the structure and production of collagen or similar proteins that interact with it. (20,21)

Very rare condition is congenital aphakia, complete absence of the lens. During development lens placode fails to develop from the surface ectoderm. Can occur with gross malformation like microphthalmia or spontaneously throughout the development lens absorbed.

Figure 20. Different stages of lens subluxation

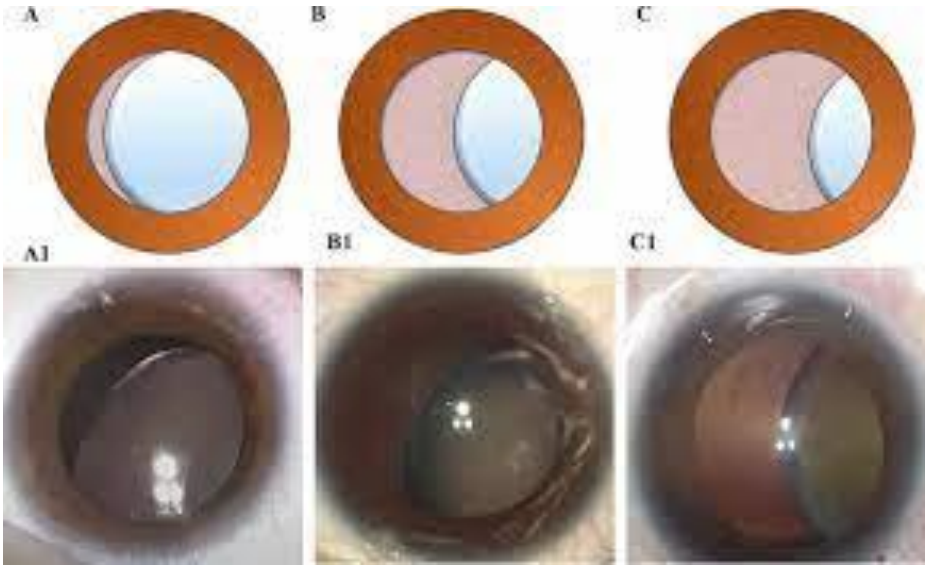

Source 20.https://www.researchgate.net/figure/Different-degrees-of-lens-subluxation-A-and-A1-Mild-lens-edge-uncovered-0-to-25_fig2_349031986 05.07.2022.

[9] Marfan's syndrome-multi systemic genetic disorder that affects the connective tissue, it is caused by change in the gene that controls fibrilin

[10] Ehlers-Danlos syndrome- a genetic disorder that affects soft connective tissue that supports skin,ligaments, blood vessels, internal organs, and bones

Figure 21. Dislocation of the lens

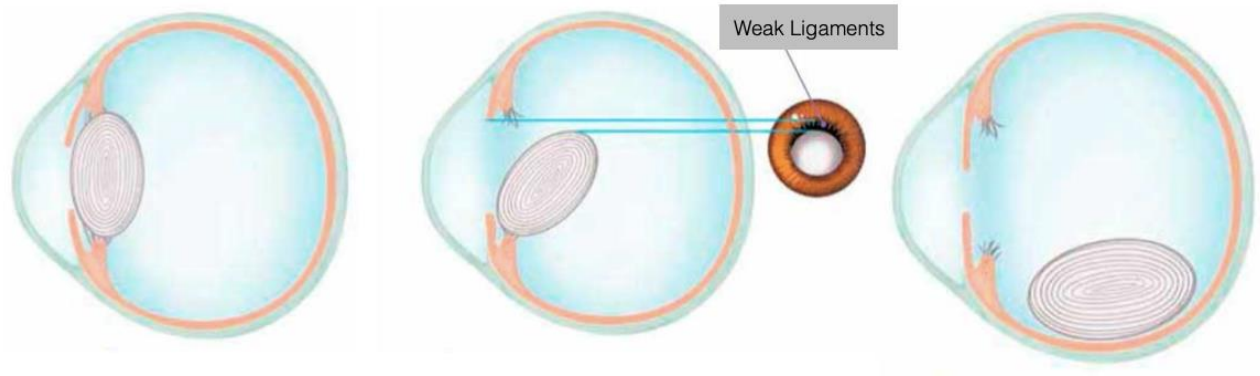

Source 21.https://www.synergyeye.com/images/posterior-dislocation-1.png 05.07.2022.

3 Cataract

Cataract is defined as any opacity of the lens and cause visual impairment in adults and also during childhood. According to the data of the World health organization (WHO) from 2009, cataract is the leading cause of blindness in the world, except in the most developed countries. It most often occurs in elderly people, which is why it is said about senile cataract. Clouding of the lens usually causes painless decrease in visual acuity, appearance of monocular double images and glare at illumination with an intense light source and a change in refraction. Refractive index can variate caused by changes in lens cell structures and lens proteins and result in increasing light scattering. During aging lens became rounder during decreases of curvature of anterior capsule. Lens epithelial cells become thinner and nuclei became flat which creates vacuoles and multilamellar bodies develop between lens fiber cells, occasionally disrupting the fiber plasma membrane. Lens proteins become water insoluble and increases opacity in the lens. Aggregation of the proteins, lens loses transparency and start to changing color from pale yellow to darker yellow and at the end to the brownish color. Any other factors chemical or physical which disturb water and electrolytes in lens bring opacification to the lens. Some of risk factors are exposure to radiation, smoking, alcohol, systemic disease like diabetes, hypertension and high levels of cholesterol. Symptoms of cataract are blurry vision, trouble seeing well at night, seeing double and sensitivity of the light. (22) Cataract can be defined by 2 types; congenital/infantile or acquired cataracts. Most common forms of cataract are nuclear cataract (NUC), cortical cataract (COR) and posterior subcapsular cataract (PSC). WHO develop cataract grading system to grade most common forms of cataract. Similar to that grade system is lens opacity classification system III. (LOCS III.) develop from form LOCS I. and LOCS II., this grade is based on changes in color and opacification. Severity is grades on decimal scale by spacing intervals regularly. According to maturity we can have immature, mature, intumescent and hyper mature or Morgagnian cataract.(23)

Figure 22. Opacity Classification System

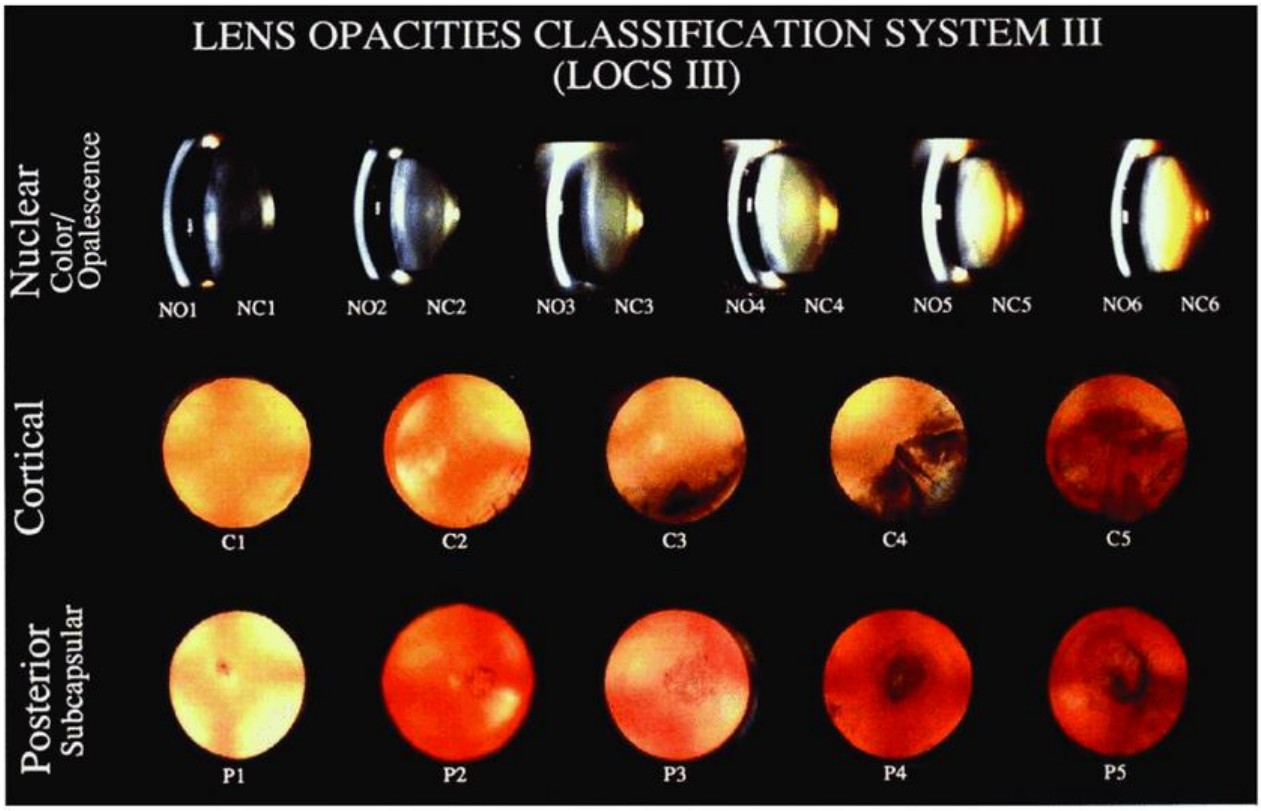

Source 22. https://www.researchgate.net/figure/Opacity-Classification-System_fig3_346858037 05.07.2022.

Figure 23. Types of catarcts

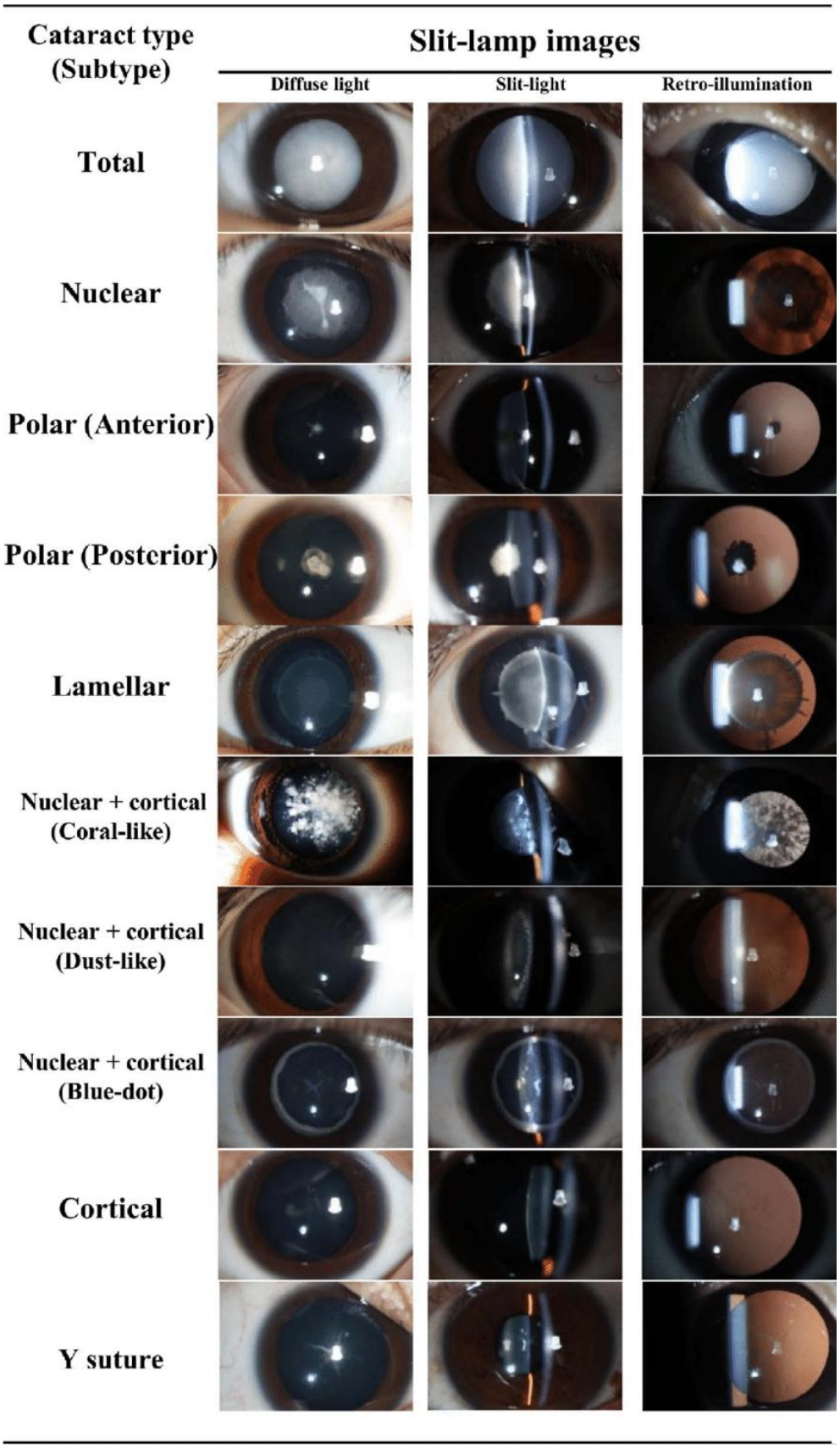

Source 23.https://www.researchgate.net/figure/Representative-slit-lamp-images-of-10-types-and-subtypes-of-congenital-cataract_fig1_320826915 05.07.2022.

When cataract is immature scattered opacities are separated by clear zone, while in mature cataract cortex is totally opaque. Intumescent cataract is when lens become swollen by imbibed water, during the leakage of water out of the lens lens capsule start to have wrinkles and become smaller than that cataract is hypermature. Last stage of maturity is morgagnian cataract in which is total liquefaction of the cortex and nucleus is sink inferiorly.

Figure 24. Classification according to maturity

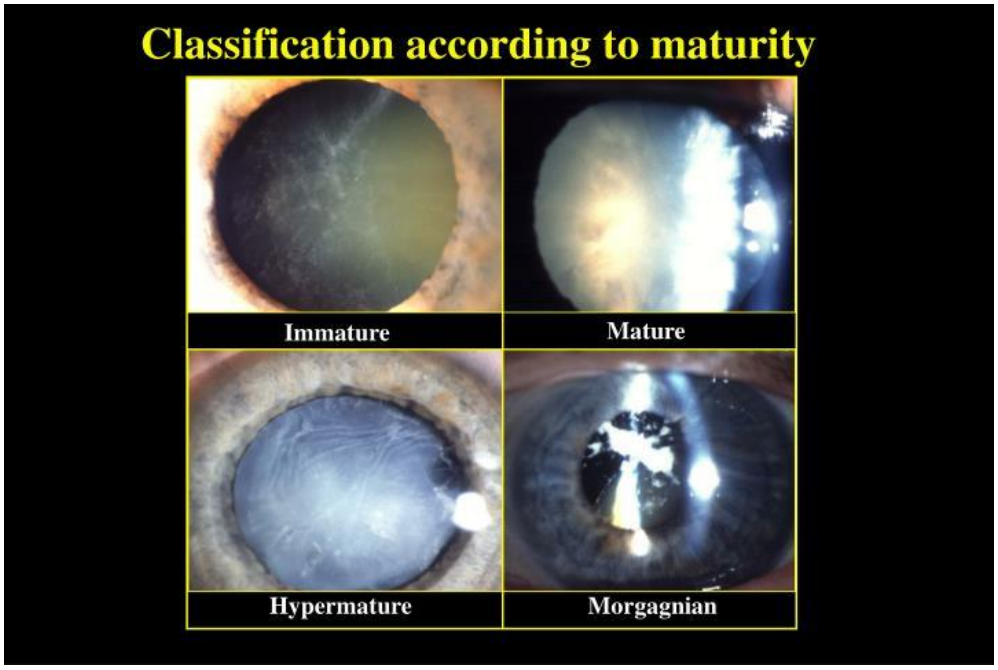

Source 24. https://www.slideserve.com/Albert_Lan/web-squ-om 05.07.2022.

3.1 Congenital or infantile cataract

Congenital or infantile cataract is termed if it is observed within the first year of life. Shiels and Hejtmancik present in research that between 8.3-25% of congenital cataracts are hereditary generally cause by an intrauterine infection e.g. rubella virus, toxoplasmosis, cytomegalovirus infections or human immunodeficiency virus. Other reasons for developing congenital cataract are drug use during pregnancy, metabolic disease like galactosaemia[11], Fabry disease[12] or hyperglycemia, or some genetic disorders like Down's syndrome, Werner's syndrome[13] or Edwards syndrome[14].(24) This type of cataract I one of the most common causes of visual impairment or blindness in worldwide.

[11] Galactosaemia- an autosomal recessive condition characterized by impairment of galactose utilization caused by an absence of enzyme galactose-1
[12] Fabry disease- a disorder caused by deficiency of the enzyme alpha-galactosidase and leads to abnormal accumulation of a glycolipid
[13] Werner's syndrome- an autosomal recessive disorder characterized by appearance of accelerated aging
[14] Edward's syndrome- trisomy 18, affects the way the baby grows and develops

Figure 25. Congenital cataract in the right eye

Source 25. http://www.squinteyehospital.com/eye_diseases/congenital_cataract.html 05.07.2022.

3.1.1 Nuclear cataract

Nuclear cataract is defined as clouding and coloration of the nucleus. It affects distance vision, can produce double vision and glare from the lights. Hardening of the lens proteins increases refractive index and increases myopic shift in refractions, referring to hyperopic individuals they become less dependent on their spectacle correction due to the nuclear cataract.

Figure 26. Nuclear cataract

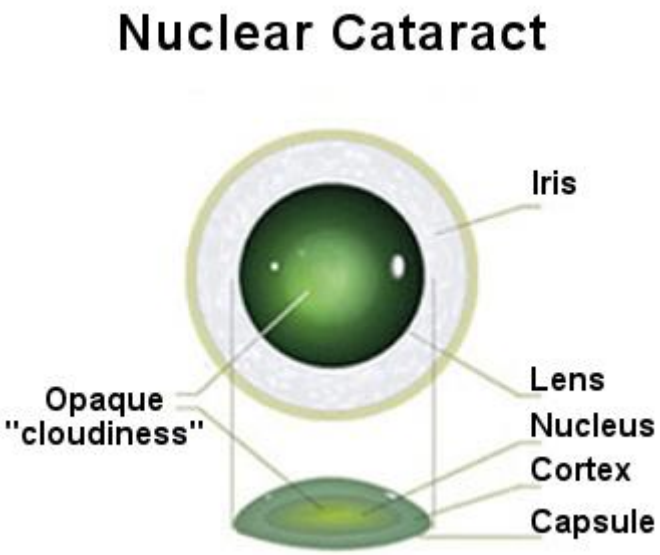

Source 26.http://prostatecancertopics.com/m/images/cataract-3d-334.jpg 05.07.2022.

3.1.2 Lamellar cataract

Lamellar or zonular cataract is when crystalline opacities are located at the level of the primary fibers in the embryonic nucleus. Usually is bilateral and asymmetrical. In some cases can involve whole nucleus and can be decrease visual acuity.

Figure 27. Lamellar cataract

Source 27.https://www.peertechzpublications.com/articles/doi10.17352-2455-1414.000048-jcro.php 05.07.2022.

3.1.3 Sutural cataract

During development of the lens fibers, we can find Y sutures which are the border between embryonic and fetal nucleus. In sutural cataract we can see opacities that affect Y sutures, they can cause minimal visual disturbance and usually do not require surgical intervention.(25)

Figure 28. Sutural opacities in fetal nucleus and Y sutures

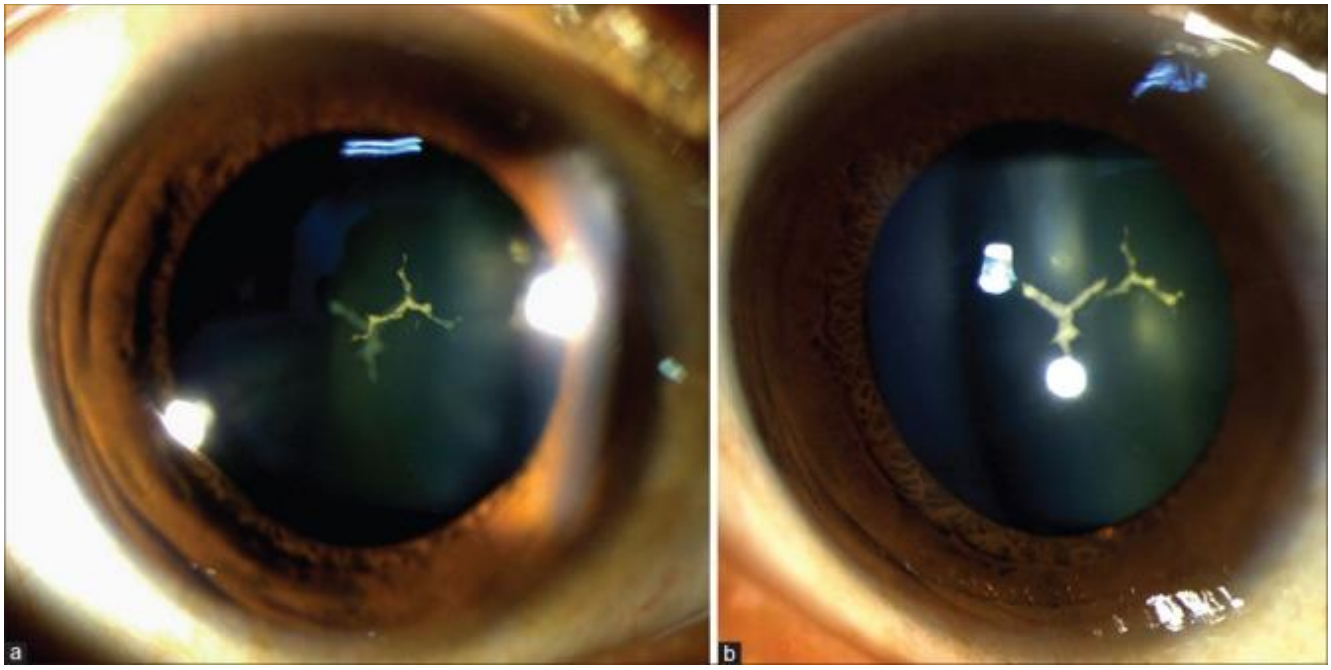

Source 28. https://www.ncbi.nlm.nih.gov/pmc/articles/PMC5989515/ 05.07.2022.

3.1.4 Polar cataract

Posterior polar cataract (PPC) is developed during lens fiber malformations where fibers migrate towards the posterior pole from the equator and result in lens opacity. Present in central dense disk-shaped opacity located on the posterior capsule with concentric rings around the central plaque opacity that appear like a bull's eye. Patients with PPC usually present with defective near and distant vision, glare, halos, and reduced contrast sensitivity. Firstly, has been thought that the PPC is remains from hyaloid artery persistence, but Ionides demonstrated in genetic research that PPC is heterogeneous disease and it's linked to five genes causing malformations on lens fibers.(26,27)

Figure 29. Posterior polar cataract

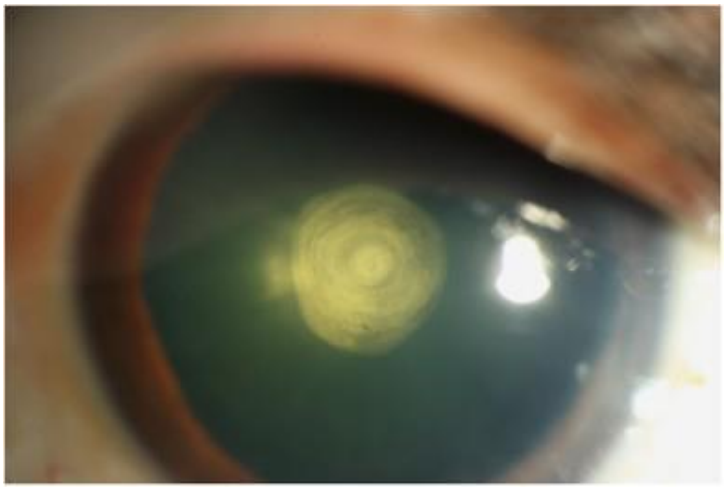

Source 29.https://www.nature.com/articles/eye201233.pdf 05.07.2022.

3.1.5 Coronary cataract

In coronary cataract opacities are arranged radially in the outer layers of the lens, leaving the center of the eye clear. These opacities surround the nucleus and appearance that is thought to resemble a crown. Often develops during puberty and after the age of 20 years of life, usually does not impair vision.

Figure 30. Coronary cataract

Source 30. https://eyerounds.org/atlas/pages/coronary-cataract-cataracta-coronaria.html 05.07.2022.

3.1.6 Blue dot cataract

Another name for this type of cataract is cerulean cataract because of blue and white opacification in the nucleus and the cortex of the lens. Mutations in beta and gamma crystalline gene cause this type of congenital cataract. Patients don't have reduced visual acuity and rarely need cataract surgery before start primary education, until they notice decreased vision. The differential diagnosis for cerulean cataracts includes other congenital, developmental and traumatic cataracts.(28)

Figure 31. Blue dot or cerulean cataract

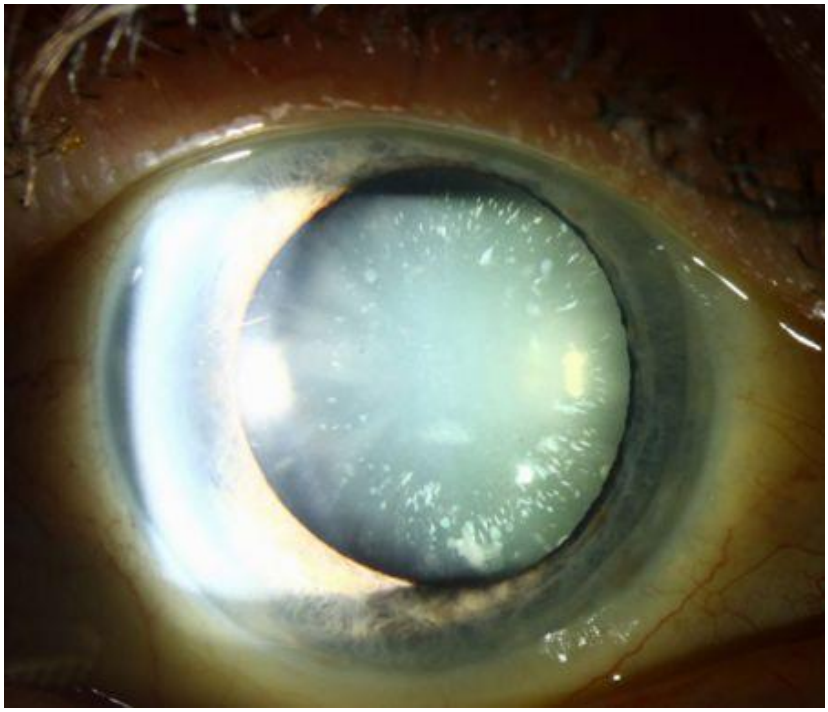

Source 31. https://eyewiki.aao.org/Cerulean_Cataract 05.07.2022.

3.2 Acquired cataract

3.2.1 Age-related cataract

3.2.1.1 Subcapsular cataract

This type of cataract has two forms, anterior and posterior . Anterior subcapsular cataract lies under the lens capsule and posterior subcapsular form lies in front of posterior capsule. Appears in shape of vacuoles, which are product of swollen migratory of lens epithelia cells. Several studies have shown that this opacities are associated with osmotic damage in superficial lens cortex which involve oxidative damage to the lens.(29) Similar opacification we can find after cataract surgery in posterior capsular opacification. Some of risk factors for developing this type of cataract are high myopia, diabetes and exposure to high doses of steroids. Patient often have more problems with near than distance vision, and conditions under miosis such as bright sunlight.

Figure 32. Posterior subcapsular catarct

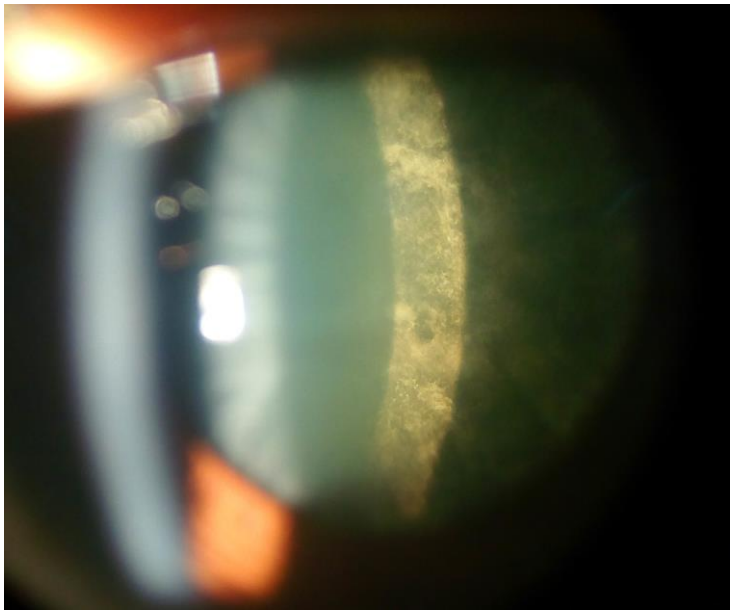

Source 32.https://commons.wikimedia.org/wiki/File:Posterior_Subcapsular_Cataract.jpg 05.07.2022.

3.2.1.2 Nuclear cataract

Nuclear cataract develops during sclerosis of the central nuclear fibers. Deposition of abnormal lipoproteins leads to reduction in glutathione formation and result with increased calcium concentration. Sclerosis gradually spreads towards the cortex and extends up to the capsule. Result of that is that entire lens starts functions as a nucleus. Due to deposition of melanin nucleus becomes firstly yellowish and at the end can become black (cataract nigra). The risk of nuclear cataracts also increases with the amount and duration of smoking. Visual acuity is decreased during myopic shift in refraction.

Figure 33. Nuclear sclerotic cataract

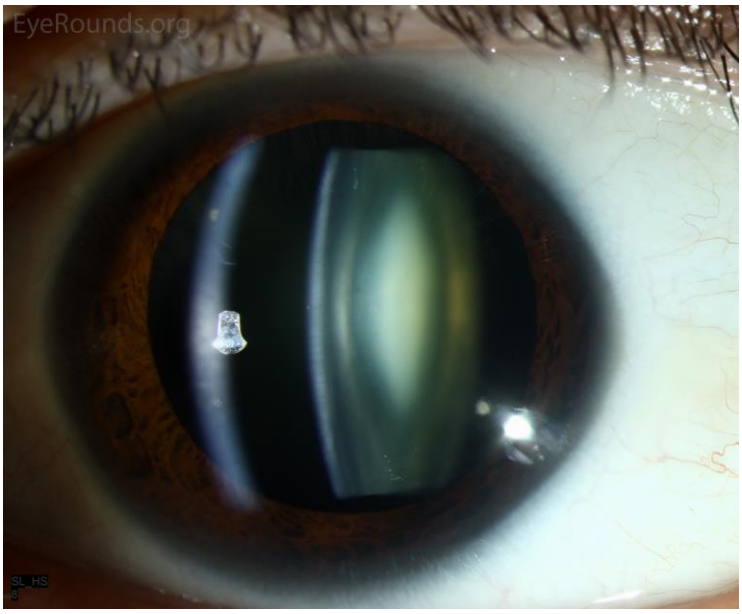

Source 33. https://webeye.ophth.uiowa.edu/eyeforum/atlas/pages/Nuclear-sclerotic-cataract/index.htm 05.07.2022

3.2.1.3 Cortical cataract

Cortical cataract can affect the anterior, posterior and equatorial lens cortex. Start as clefts whitish opacities on the outer edge of the cortex. Often in the inferonasal quadrant During slow progresses streaks extend to the center and block light passing through the center of the lens. Patients with cortical opacities complain of glare due to light scattering.(30)

Figure 34. Cortical cataract

Source 34.https://www.verywellhealth.com/types-of-cataracts-3421562 05.07.2022.

3.2.1.4 Christmas tree cataract

A Christmas tree cataract is a rare condition resulting from accelerated breakdown of membrane proteins induced by elevated calcium levels. On slit-lamp examination we can see small needle like crystals with variety of colors. Typically is idiopathic or associated with myotonic dystrophy.

Figure 35. Christmas tree cataract

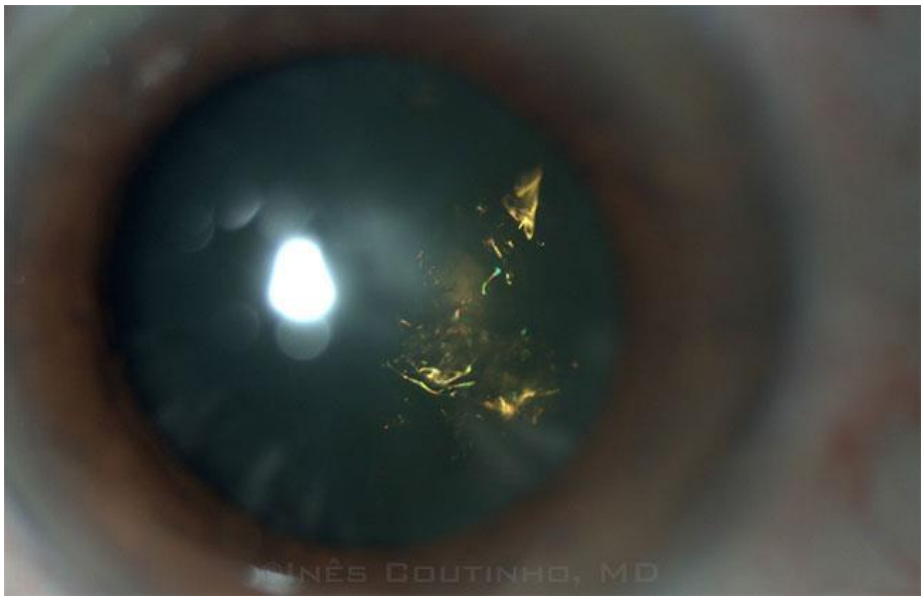

Source 35. https://www.aao.org/eyenet/article/christmas-tree-cataract 05.07.2022.

3.2.2 Systemic disease cataract

3.2.2.1 Diabetes mellitus

High level of glucose in the aqueous humour metabolized into sorbitol and accumulates within the lens, result of that is osmotic overhydration. That affect refractive index of the lens and amplitude of accommodation and can show fluctuation in refraction status (shift to myopia). Vacuoles filed with the fluid develop opacities. Snowflake cortical cataract is classical diabetic cataract, often occurs in young patients and may resolve spontaneously or can mature in few days. The Beaver Dam Eye Study reported an association between diabetes and cataract formation. It showed an increased incidence and progression of cortical and posterior subcapsular cataracts for DM patients. (31)

Figure 36. Snowflake cataract

Source 36.https://www.aao.org/image/diabeticsnowflake-cataract-2 05.07.2022.

3.2.2.2 Myotonic dystrophy

Patients with myotonic dystrophy[15]develop cortical opacities, some-times resembling Christmas tree cataract. These evolve into visually disabling wedge-shaped cortical and subcapsular opacities, often star-like in conformation.

3.2.2.3 Atopic dermatitis

Atopic dermatitis is an allergic disorder associated with chronic eczema and asthma. About 10% of patients with severe atopic dermatitis develop cataracts, they are often bilateral and may mature quickly. Using topical and systemic corticosteroids in therapy have been implicated in the development of cataracts. Posterior subcapsular cataract is more common overall in patients with atopic dermatitis.(32)

Figure 37. Shield-like anterior subcapsular cataract in atopic

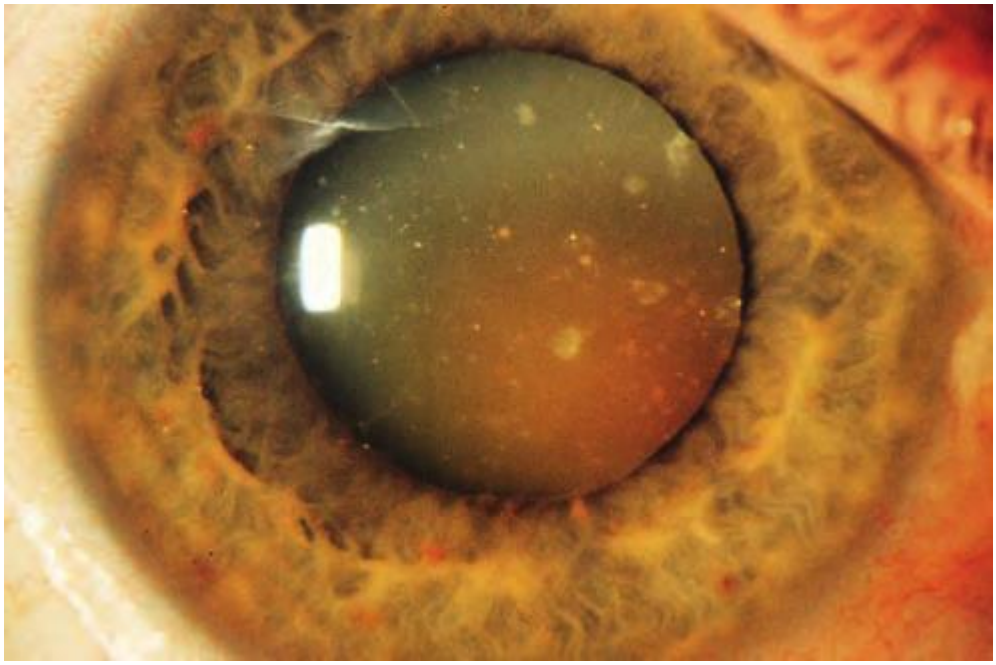

Source 37.https://entokey.com/lens-10/ 05.07.2022.

3.2.2.4 Neurofibromatosis

It is a genetic condition that causes tumors to grow along nerves. Cataract affects about two-thirds of patients. The opacities may be posterior subcapsular or capsular, cortical or mixed.(33)

[15] Myotonic dystrophy-type of muscular dystrophy that cause progressive muscle loss and weakness

3.2.3 Secondary cataracts

3.2.3.1 Chronic anterior uveitis

Most common cause of secondary cataract, it is being related to the duration and intensity of inflammation. Another reason is also prolonged use of high-dose topical and/or systemic corticosteroids. During inflammation, posterior and anterior opacities develop.(34)

3.2.3.2 High myopia

High myopia can be associated with posterior sub- capsular lens opacities and early-onset nuclear sclerosis, which increase the myopic refractive error. Brown and Hill made study on 100 patients presenting with cataract and myopia whom they now refraction four years prior development of cataract. They conclude that simple myopia does not appear to predispose to cataract.(35)

3.2.3.3 Hereditary fundus dystrophies

The hereditary fundus dystrophies are a group of disorders that commonly effect on the retinal pigment epithelium, photoreceptor complex and the choriocapillaris to cause a range of visual impairment. Most common dystrophy is retinitis pigmentosa, Leber congenital amaurosis and Stickler syndrome. They are associated with posterior and anterior subcapsular cataract. Even with presence of retinal changes cataract surgery may improve visual function.(36)

3.2.3.4 Acute congestive angle closure

After acute angle closure attack, we may see grey-white opacities form within pupillary area. called glaukomflecken. Usually, they laid under the anterior capsule and present focal infarcts of the lens epithelium.(37)

Figure 38.Glaukomflecken

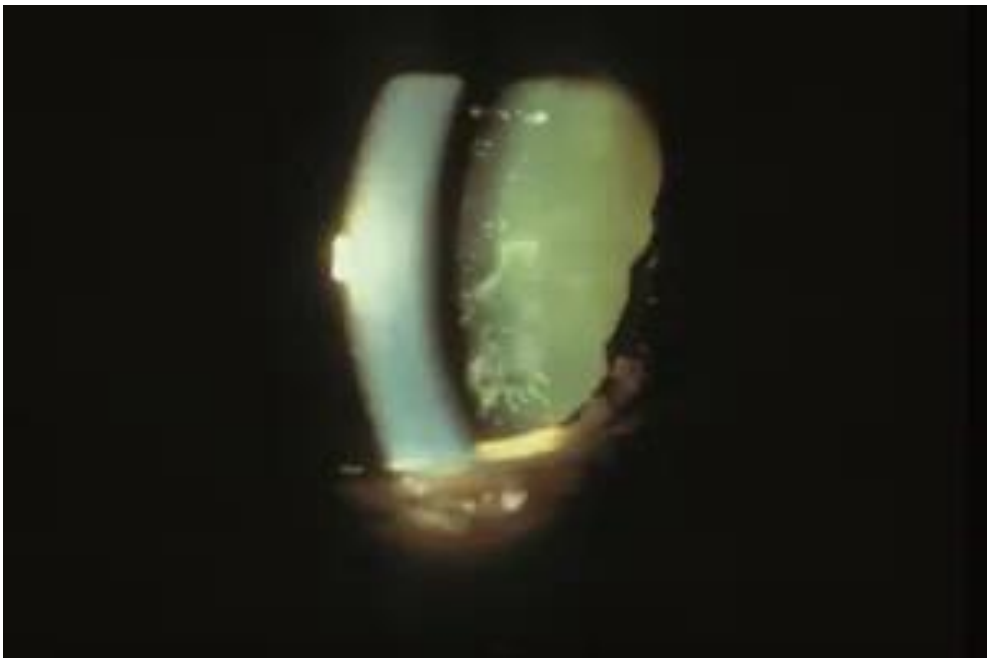

Source 38.https://www.aao.org/image/glaukomflecken-4 04.08.2022.

3.2.4 Traumatic cataract

Clouding of the lens that may occur after either blunt or penetrating ocular trauma that disrupts and damages the lens fibers. Traumatic cataracts lead to lens swelling, but the type and clinical course depends on trauma and the integrity of the capsular bag. Over a period of time lens becomes progressively opaque even lens capsule is not extensively damaged. Direct rupture and distortion of capsule coup results from the expansion of the force transferring the energy affecting the other side of the eye. Some of symptoms are discomfort and pain, blurry vision, anterior chamber cell reaction and corneal edema.

Figure 39. Flower shape traumatic cataract

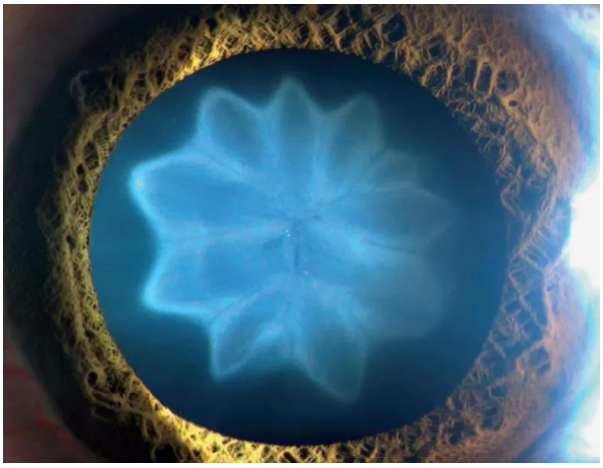

Source 39. https://www.livescience.com/54655-flower-shaped-cataract-eye-injury.html 04.08.2022.

4 Management of age-related cataract

Cataracts are simply observed by slit-lamp examination and can be treated with a spectacle correction. Important is to emphasize that cataract progression can be slowed with better control of underlying diseases and excluding risk factors such as smoking and exposure to UV radiation. If the opacification is visually significant and the patient's vision cannot longer improve with spectacles, the opacified lens need to be surgically removed and replaced with a synthetic intraocular lens (IOL). Another reason for cataract surgery is loss of stereopsis, decreasing of peripheral vision, symptomatic anisometropia or medical indication for surgery for glaucoma or dislocation of the lens. Some of aims of cataract surgery are restoration of vision, improvement quality of life, reduced poor vision at distance and near, management of refractive error and clarity of ocular media for treatment of fundus pathology.

4.1 Preoperative assessment

The patient ocular history should reveal whether the vision loss was of acute or gradual onset. It is unusual for a cataract to cause an acute onset of vision loss but sometimes a cataract may have been present for years but detected only when the vision in the better eye was compromised. Medical history and history of general health including diabetes, hypertension, lung disease, bleeding disorders or heart disease should be recorded due to influence on the operation itself, but also on the recovery after the operation. Systemic alpha-blockers are associated with intraoperative floppy iris syndrome, therapy for anticoagulation or antiplatelet should be in the same range which is appropriate for individual diagnosis (disease). Patient should state if have some allergies or intolerance on medications that are used after cataract surgery.

4.1.1 Preoperative examination

4.1.1.1 Visual acuity and slit-lamp examination

Detailed evaluation is required and should consider refractive status on distance and near, by Snellen chart despite limitations. Ocular motility should be evaluated, if patients have tropia or phoria may develop symptoms after surgery in the change in refraction causes motility status to break down. Ocular adnexa is examined for abnormalities. Lid position abnormalities, presence of blepharitis or dysfunction of Meibomian glands, discharge regurgitating on pressure over the lacrimal sac require attention prior to cataract surgery. Presence of conjunctival congestion warrants investigation and possibly postponement of surgery. An abnormal tear film may delay wound healing and be the cause of postoperative discomfort attributed by the patient to the surgery. The corneal endothelium should be examined for signs of Fuchs dystrophy, Krukenberg spindles, or signs of previous iritis. Any of these diseases can delay the healing course of the eye, leading to corneal edema or high intraocular pressure after surgery. The iris surface should be examined for areas of atrophy, alteration in the pattern and neovascularization. The pupils should react briskly to light even in the presence of very advanced cataracts. A sluggish response or a relative afferent pupillary defect makes the prognosis for restoration of vision after cataract surgery extremely poor. In order to expect good visual acuity after replacing crystalline lens with IOL it is mandatory to make fundus examination. Pathology such as diabetic macular edema and wet age-related macular degeneration should be treated and dried up with anti-VEGF injections as much as possible before surgery because they can adversely affect visual outcome. After taking preoperative information's from patient, important part in preoperative assessment is explanation and discussing benefits and risks from surgery with patient. Surgery is often performed on one eye at a time, separated by several weeks. Several trials have found that surgery in both eyes at the same time is cost effective, improves patient visual symptoms, and may reduce the risk of falls and automobile accidents.(38)

4.2 Biometry

Optical biometry facilitates calculation of the lens power is basic form that involves the measurement of axial length (AL), anterior chamber depth (ACD), lens thickness (LT), central corneal thickness (CCT), pupil size (PS). All this values with keratometry are essential for intra ocular lens (IOL) power calculation. Precision of measurement is crucial and can result in a refractive error after surgery. In European Ophthalmic Review we can find the data that show that 0,01mm error in AL result in 0,27 diopter (D).(39) Optical biometry measures the distance from corneal surface to the retinal pigment epithelium, it is non-invasive and non-contact method and can be performed in pseudophakic or silicone oil-filled eye. Before optical biometry devices for many years was used ultrasound biometry for measure the AL. Today, we can see the use of ultrasound biometry in presence of dense cataract. Ultrasound biometry measures the distance from the surface of the corneal apex to the internal limiting membrane. During this procedure is required to use topical anesthetic because probe has direct contact with the cornea and is high risk of corneal damage and infection. Depending on pressure exerted on the eye with ultrasound probe can result in corneal indentation and shortening of the AL. Another option during the ultrasound is to use saline-filled shell between the probe and the eye, to minimalize the indentation to the cornea. Some studies has shown that using saline filled shell is more reliable than performing in contact mode. (40). As gold-standard biometer currently is used IOLMaster 500 (Carl Zeiss), it was first optical biometer introduced 1999. It is based on the partial coherence interferometry (PCI) and measures AL using infrared light of short coherence emitted by semiconductor laser diode. Analyzing the anterior corneal curvature at six points at 2.3 mm optical zone measures keratometry. Measuring the ACD is defined as a distance from corneal epithelium to the anterior lens surface and is measured using slit-lamp illumination. Another type of instruments used for optical biometry are based on optical low coherence interferometry (OLCR), most popular devices in that group are Lenstar LS 900 (Haag-Streit), Aladdin (Topcon) and Galilei G6 (Ziemer). The difference is in the source of the light and optical settings of their interferometers.(41) Purpose of biometry is to get data for calculation of IOL. In calculation formula we need AL and keratometry, other data are constant and depends on design of lens and producer. Calculation of the IOL power can be performed using a variety of formulas the newest, fourth generation of formulas have advantage of including the relationship between the ACD and AL which should provide the highest accuracy over the IOL power.

Figure 40. Ultrasound biometry of the eye

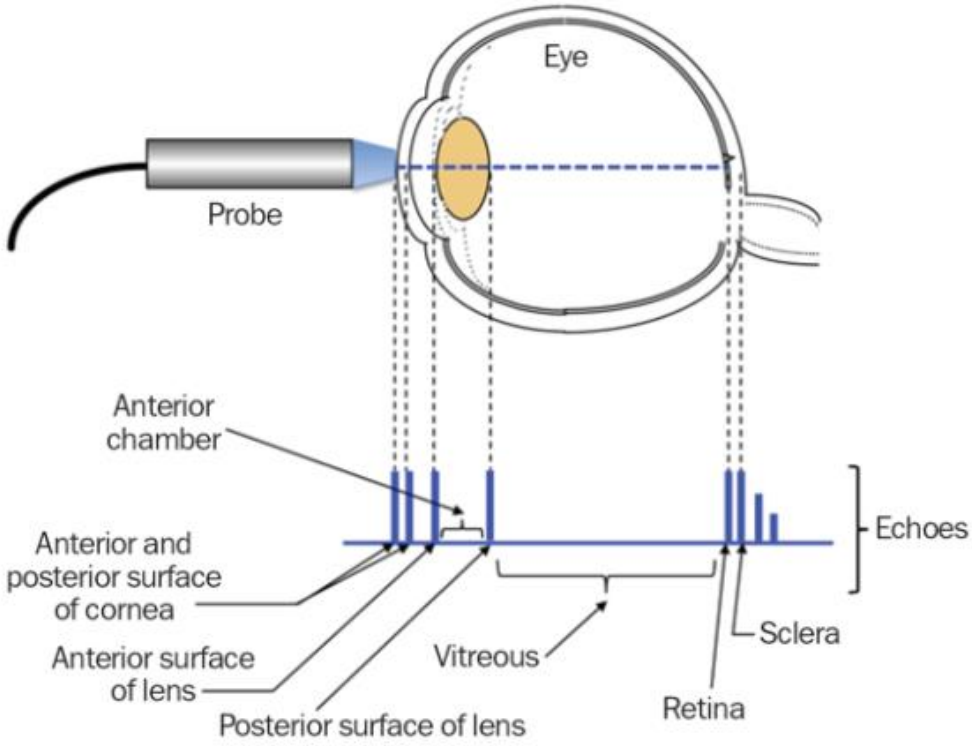

Source 40. http://www.retinapodcast.com/equal-round-and-reactive/2019/3/31/lessons-from-our-pupils-a-reflection-podcast-episode-154 15.07.2022.

Figure 41. IOLMaster 500

Source 41. https://www.zeiss.com/meditec/en/products/optical-biometers/iolmaster-500.html 15.07.2022.

4.3 Intraocular lenses

Before 1949. there were no IOLs to replace natural lens after cataract surgery. Therefore, after surgery, patients had to wear 'cataract glasses' with a large plus diopter (from +10 to +14 diopters) for correction of high hyperopia. During World War II., English ophthalmologist Harold Ridley noted after plane crashes in eyes of injured pilots' material that was not rejected by body and not cause an inflammatory reaction. That scraps were from cockpit windshield made of polymethyl methacrylate (PMMA) [16]. After, he implanted the first one PMMA intraocular lens after extracapsular cataract extraction. (42) During cataract surgery, eye's natural lens replaces with tiny artificial lens. The materials used to make the IOL lens are polymers and can be divided into two main groups: acrylate and silicone. The edges of the IOL must be as sharp as possible, because it has been proven that the sharper the edge of IOL, the less occurrence of posterior capsule opacities (PCO) and less need treatment with yttrium aluminum garnet (YAG) laser. Guided by fact that one of leading causes of blindness in development world is age-related macular degeneration, some models of the last generation of IOLs have built-in filters for ultraviolet (UV) light and blue light due to possible protective effect on the retinal pigment and the macula itself.(43)

4.3.1 Intraocular lens implants

Intraocular lenses are divided into monofocal, multifocal, accommodating and toric IOLs. The most common type which is used is monofocal IOLs and it has one focusing distance. In most cases they are set for clear vision on distance and for reading or close work you need to wear glasses. In 2005. Food and Drug Administration (FDA) approved multifocal and accommodative lenses, which have diffusing optics light so that they have more focus in different points simultaneously These lenses reduce dependence on glasses giving a clear vision at the same time on distance, medium range and close up work. Accommodative lenses are powered by eye muscles and change shape which allows focusing on different distances. Theoretically mimic the natural accommodation of the eye, with the help of an aspheric design and flexible holders. Flexible mounts allow the lens to move slightly forward when viewing close-up objects, increasing focusing power. In this way, the accommodative IOL lens provides better near vision than the usual monofocal lens. After implanting multifocal lens some optical side effects that are reported include halos, glare and decreased contrast sensitivity. Monofocal and multifocal lenses can only correct the spherical component of the eye leaving behind the cylinder power which has to be later corrected by additional prescription glasses or contact lenses. Toric IOLs are lenses which can resolve long-standing problem of astigmatism, also on market are available monofocal toric and multifocal toric IOLs.(44) Special markers on the peripheral parts of the lens enable the surgeon to see the orientation of the astigmatism correction. When the toric IOL is implanted in the eye, the surgeon rotates the lens so the astigmatism correction is properly aligned for best results. Problem with toric IOLs is that they can rotate in the capsular bag causing reduction or neutralization of the astigmatism correction, which involves another surgery to rotate the lens back into the correct position. In 2016., FDA approved extended-depth-of-focus (EDOF) IOLs, lenses that primarily improves intermediate visual acuity, mostly useful for computer work but also provide good distance and near vision. This type of IOLs is between monofocal and multifocal lenses and correct problems such as glare and lower contrast sensitivity. They are based on principle that produce single focal point with extended depth that offers clear distance to near vision and is achieved by small degree of optical aberration. (45)

[16] PMMA- belong to gorup of materials called engineering plastics also known as transparent thermoplastic

Figure 42. EDOF IOL

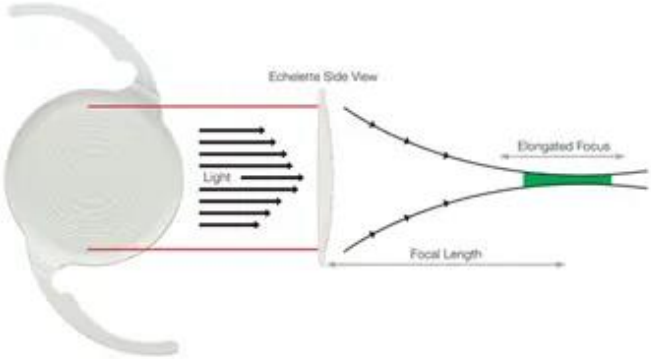

Source 42.https://d31g6oeq0bzej7.cloudfront.net/Assets/image/webp/a8909d84-113d-427a-a706-e9cd139c26bc.webp 15.07.2022.

Figure 43. Multifocal IOL

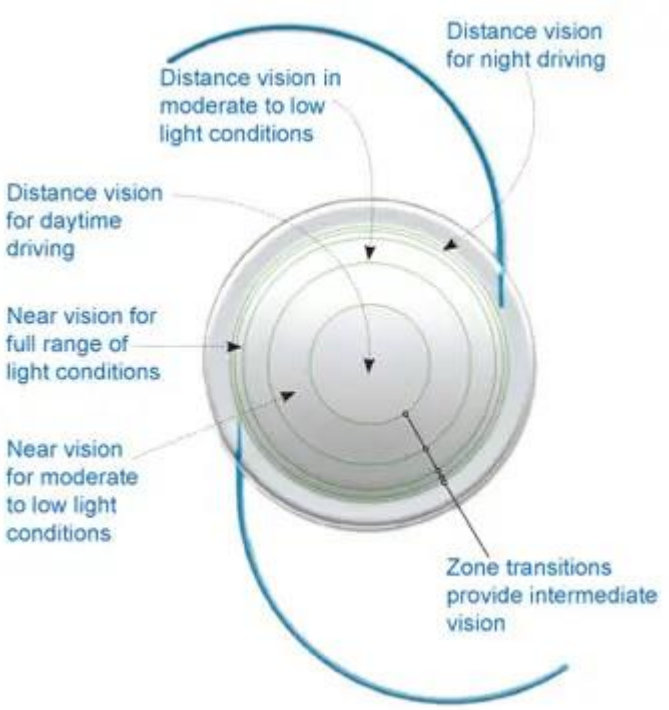

Source 43.https://williamseye.com/services/advanced-cataract-treatment/rezoom-multifocal-iol/ 15.07.2022.

Figure 44. Toric IOL

Source 44. https://www.allaboutvision.com/conditions/toric-iols.htm 15.07.2022.

Figure 45. Monofocal IOL

Source 45.https://www.zeiss.com/meditec/en/products/iols/monofocal-iols/ct-asphina-family.html 15.07.2022.

4.3.1.1 Iris fixated intraocular lenses

Iris-fixed lenses also called "iris-clip" lenses with four loops, two in front and two behind the iris, of which the upper loops are usually sewn into the iris to prevent the main complication of dislocation implant. Because of sewing, the result is a square pupil, another problem is metal clips on the IOL and after surgery, the patient cannot be dilated pupils. Due to their shortcomings and complications, these types of lenses have been abandoned today. (46)

Figure 46. Iris fixated IOL

Source 46. https://eyeillustrations.com/eye-illustration/iris-fixated-intraocular-lens/ 15.07.2022.

4.3.1.2 Anterior chamber intraocular lenses

These implants can be divided into two groups depending on type of holders, it can be rigid or elastic that maintain the optical part of the IOL in the area of the anterior chamber in front of the pupil. The IOL must be positioned that does not touch the endothelium of the cornea, to be fixated and to close anterior chamber as little as possible. Many research shows that result of anterior chamber IOLs surgery is increased endothelial cell loss and keratopathy. This type of surgery applies when the lens capsule or zonules are damaged .(47)

Figure 47. Anterior chamber IOL with four- and three-point fixation design



Source 47. https://entokey.com/evolution-of-intraocular-lens-implantation-2/ 15.07.2022.

4.3.1.3 Posterior chamber intraocular lenses

Posterior chamber IOLs are placed in the capsular bag or sometimes anchored into the ciliary sulcus so another name for this type of IOLs are sulcus supported lenses. The IOL is secured in the ciliary sulcus by suturing the haptics to the sclera at the ciliary sulcus inferiorly and to the sclera or iris superiorly. This type of lens is most often implanted after cataract surgery. (48)

Figure 48. Posterior chamber IOL in ciliary sulcus

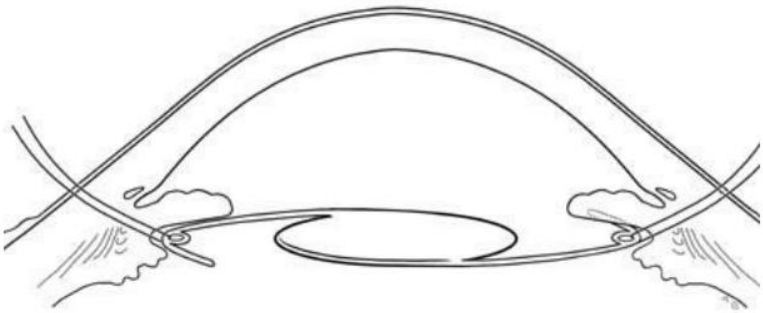

Source 48.https://image.slideserve.com/1482821/slide6-n.jpg 15.07.2022

4.4 Surgery

The two basic methods of cataract surgery are intracapsular extraction cataracts (ICCE) in which the lens is removed with the lens capsule and extracapsular cataract extraction (ECCE) in which the lens is removed and

the capsule remains in its natural position. Other newer methods that are used are phacoemulsification and femto laser cataract surgery. The most commonly used technique in surgery is phacoemulsification. Surgery is performed under local anesthesia with oral sedation or intravenous sedation. Types of local anesthesia are topical, peribulbar and Subtenon's. In some circumstances such as children, very anxious patients or patients with dementia can be given general anesthesia. Before starting surgery patient get pre-operative anesthetic and dilating drops, into a anterior chamber surgeon inject anesthetic to increase topical anesthesia and remove discomfort during surgery. To protect endothelial layer of the cornea and to provide working space is injected viscoelastic gel and creates corneal incision. Capsulorhexis is opening in the anterior capsule to get access to the cortex and nucleus of the lens. An ultrasound probe with energy breaks up the nucleus and vacuum removes nucleus fragments. After removing nucleus, cortex is aspired and pulled away avowing tearing of the capsule and some condition like leakage of the vitreous into anterior chamber. In clear capsular bag is put ophthalmic viscoelastic device to create space for IOL, the IOL is insert through a tube and uncurls automatically. IOL have 2 haptics, and is placed behind the iris or in front of iris. When the IOL is inserted, hydration of corneal incision causes corneal epithelial cells to expand and compress each other and allows wound to closure without sutures. During surgery can be put intracameral antibiotic to reduce incidence of post-surgical complication like endopthalmitis, or topical antibiotic drops as well topical steroids.

4.4.1 Intracapsular cataract extraction (ICCE)

Intracapsular cataract extraction is a method in which it is removed the entire lens together with the capsule. It is rarely performed, usually with enlarged cataracts instability and increased risk of intraoperative dislocation of the lens into the vitreous. The operation is performed through a corneo-scleral incision 8-12 mm long. IOL is implanted in the anterior chamber, and in the case of implantation in the posterior chamber, the lens needs to be fixed to the sclera or iris.(49)

Figure 49. Intracapsular cataract extraction

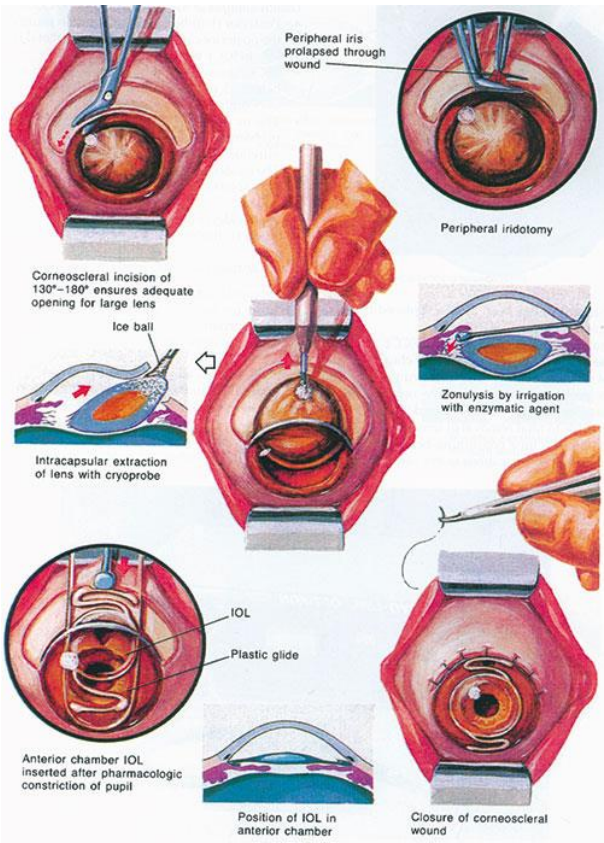

Source 49.https://img.tfd.com/MosbyMD/thumb/cataract.jpg 15.07.2022.

4.4.2 Extracapsular cataract extraction (ECCE)

Extracapsular extraction involves removing the lens from its capsule, which is kept inside the eye and acts as a barrier between anterior and posterior segments, and forming the most common place for implanting an IOL. When performing classical ECCE and implantation IOL is made of hard PMMA material and operative corneo-scleral incision is at least 7-8 mm. Such a large incision leads to postoperative complications which are relatively common, and postoperative astigmatism is also common, resulting in bad postoperative vision results.

Figure 50. Extracapsular cataract extraction

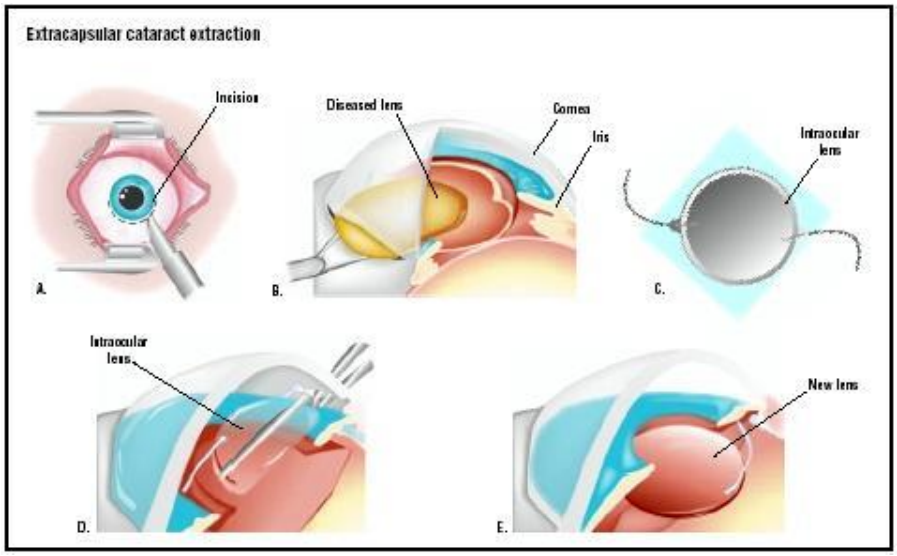

Source 50.https://www.surgeryencyclopedia.com/Ce-Fi/Extracapsular-Cataract-Extraction.html 15.07.2022.

4.4.3 Phacoemulsification (PHACO)

Phacoemulsification (PHACO) is a method of ECCE using ultrasound and is ''gold'' standard in cataract surgery. It is performed through an incision on cornea only 2-3 mm in size. Using an ultrasound probe, the nucleus of the lens is crushed with simultaneous aspiration of the crushed pieces of the lens. The basic problem in the beginning development of this method was damage to the corneal endothelium by free radicals and ultrasound energy. Solution of this problem was solved by the progress of surgical technique and technology and with the development of special viscoelastic gels. This gels coat and protect the endothelium of the cornea, also help in formation of the space inside the capsule to provide manipulation inside the anterior chamber and lens capsule. After developing gels, it was necessary to develop flexible IOLs that can be implanted through an incision width less than 3 mm. Advantages of this method are possibility of a small incision, faster wound healing, early stabilization of refractive errors and shorter recovery.(49) The Harvard Health Publishing in 2020 reported that through phacoemulsification 98% of all cataract cases are successful.

Figure 51. Phacoemulsification

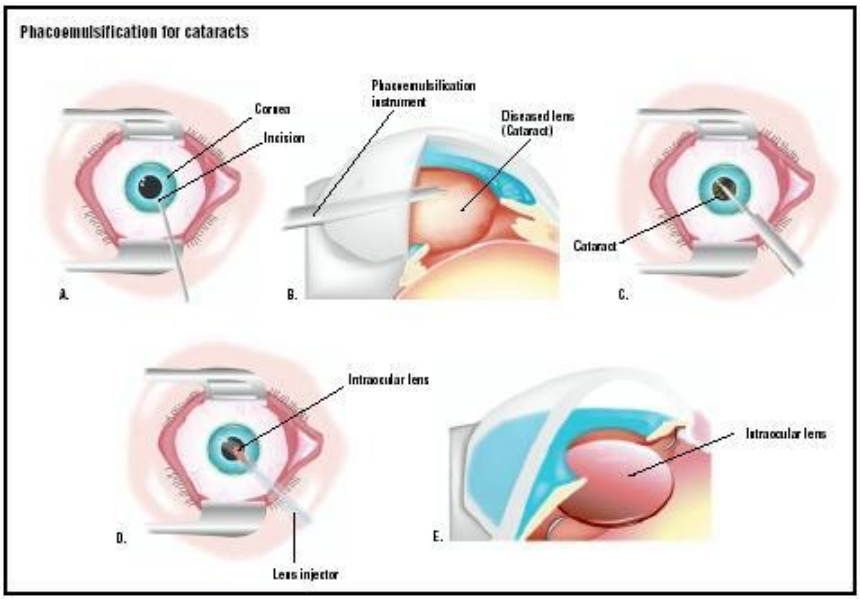

Source 51.https://www.globehealer.com/procedures/phacoemulsification-phaco-and-iol/ 15.07.2022.

4.4.4 Femto laser assisted cataract surgery (FLACS)

Femtosecond laser surgery is the new procedure of cataract surgery. Using optical coherence tomography, laser gets information of exact location, size and depth for incisions and is made in the capsule bag which allows access to the nucleus. After entrance, laser use pulses energy near the infrared spectrum in a very short duration (10-15 seconds) to soften the cataract. Ultrasound probe breaks the lens and suctions out on that way ultrasound probe is reduced to a minimum. In research made by Romanian Society of Ophthalmology, where they compare PHACO method and FLACS, conclude that after laser surgery was increased the stability of the replacement IOLs (due to the precision of the laser making the hole in the capsule bag). Another conclusion was that benefits of FLACS are self-sealing corneal wounds and more precise and better-centered capsulotomy will lead to a reduced number of complications.(50)

Figure 52. Laser cataract surgery

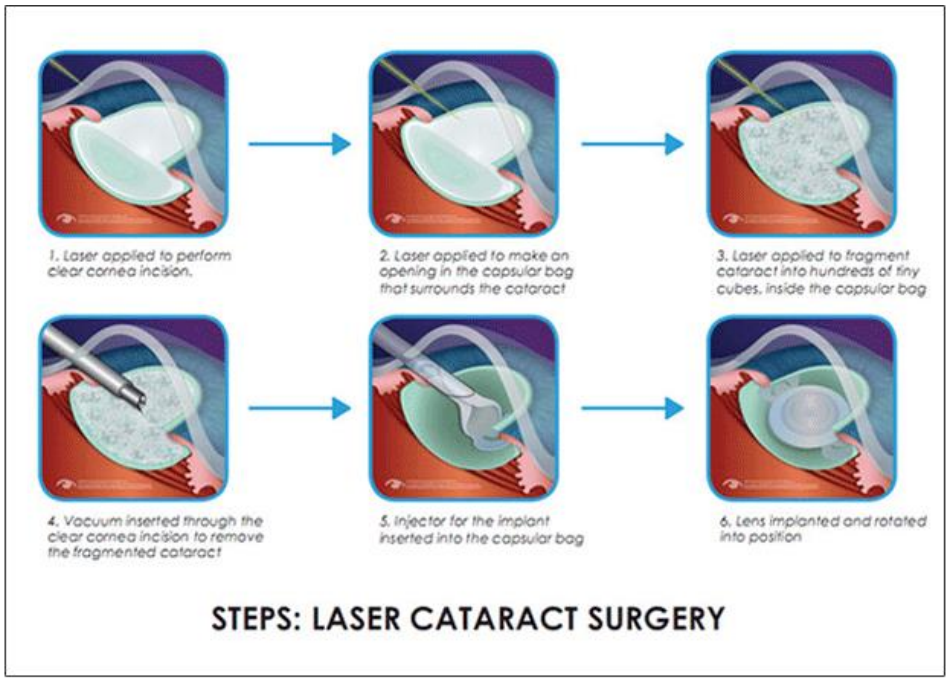

Source 52.http://occeyecare.ca/pages/femtocataract 15.07.2022.

4.5 Post-surgery treatment

Postoperative care usually includes topical steroid or nonsteroidal anti-inflammatory drug for a period of two to four weeks, as well as antibiotics for about a week. Artificial teras are given to prevent dry eye syndrome and to give comfort after surgery. The patient should be informed that avoid rubbing or putting pressure on the operated eye, sleeping on that side of the body or lifting heavy load for the first week after the operation. It is important to tell the patient to report to the doctor immediately if new or worsening symptoms appear, so that potentially serious complications can be properly treated. At first visit (24h after surgery), it is measured patient's visual acuity, intraocular pressure and by slit lamp should be evaluated conjunctiva, cornea, anterior chamber and the IOL. On second visit (7-14 days after surgery) are performed the same tests as on first visit and if is indicated by signs or symptoms dilated fundus examination. After examination patient should be informed for taper or to continue antibiotic or steroid drops. 3-4 weeks after surgery is third visit, examination is the same as for second visit, this time refraction may be performed and spectacles may be prescribed if needed. Final postoperative visit is required 6-8 weeks after surgery, and the same test are performed as for first three visit. If is not done earlier, prescription for glasses and dilated fundus examination. Prescription for glasses or contact lenses depending on type of IOL that is insert during surgery.

4.6 Complication after cataract surgery

After cataract surgery in first period (1-10 days) lens particles, inflammatory debris or pigment cells may obstruct trabecular meshwork and cause elevation of the intraocular pressure. Elevation is transient and giving antiglaucoma medication pressure will return to baseline or lower. Corneal edema is result of trauma and inflammation and patient can be present with blurry vison and foreign body sensation or pain. On slit lamp examination we can find microcysts, stromal edema and folds in Descemet's membrane. If cornea was healthy preoperatively, edema should resolve within 1 to 2 weeks. One of the most common complications after cataract surgery is the development of a posterior capsular opacity (PCO), which occurs in 50% of eyes within 5 years of surgery. The PCO occurs as the result of cell proliferation and extends from the equator of the lens capsule to the posterior surface. This can be treated with YAG laser making the small holes in the capsule that allows light to pass through and give clear vision. Similar condition that can be found in post operative cataract patients is Elschning's pearls. Accumulation of clusters from proliferated epithelial cells appears like soap bubbles can cause decreased vision if migrate to posterior capsule.

Figure 53. Posterior capsular opacification

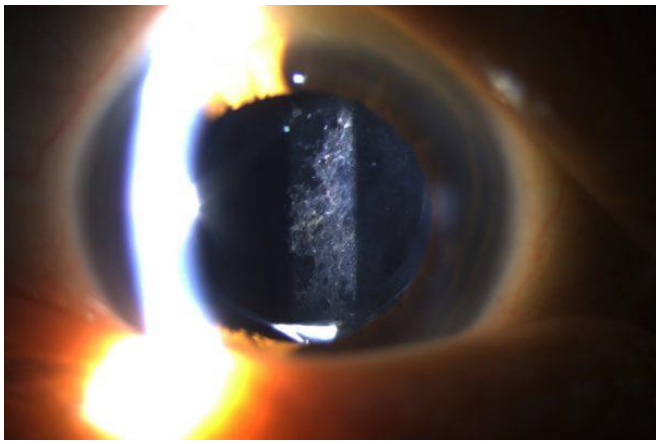

Source 53. https://www.asiapacificeyecentre.com.sg/eye-conditions/posterior-capsule-opacification-pco/ 15.07.2022.

Figure 54. Corneal edem

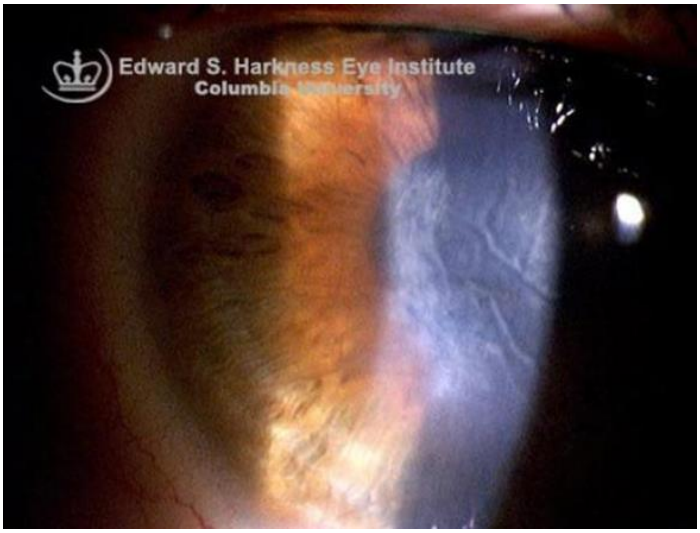

Source 54. https://www.vagelos.columbia.edu/departments-centers/ophthalmology/education/digital-reference-ophthalmology/lens-and-cataract/surgery-and-complications/corneal-edema 15.07.2022.

Figure 55. Elschnig's pearls

Source 55. https://www.vagelos.columbia.edu/departments-centers/ophthalmology/education/digital-reference-ophthalmology/lens-and-cataract/surgery-and-complications/elschnigs-pearls 15.07.2022.

More rare complications after cataract surgery are cystoid macular edema, endopthalmitis, retinal detachment, vitreous hemorrhages, intraocular lens dislocation or toxic anterior segment syndrome (TASS). Endophthalmitis is postoperative intraocular infection and can be developed in first 7 days after surgery. Patient is present with pain, loss of vision, lids and corneal edema and conjunctival infection. On slit lamp examination we can find accumulation of cells and protein in anterior chamber and in the aqueous and in pupillary area may be present fibrinous membrane. Patient with these symptoms need to be referred to the doctor because of ocular emergency. Cystoid macular edema (CME) is result of increased permeability of parafoveal capillaries and leakage occurs in the intraretinal layers. Leakage causes loss of vision and cysts in the macula. Some studies shown that number of untreated CME after surgery resolve in 5-8 weeks and restore visual acuity. Management depends on symptoms, if there is no improvement patient can get nonsteroidal anti-inflammatory and topical steroid agents. Retinal detachment or retinal break usually occurs within 6-8 months after surgery. The incidence increases if during surgery capsular bag is damaged and causing vitreous prolapse and loss. Intra ocular lens dislocation occur when the IOL is not located symmetrically with the pupil and maintain the tissue support. This can happen either with posterior and anterior IOLs and requires surgical correction. TASS is developed as response to retained lens and is toxic intraocular reaction, patients are present with blurred vision during corneal edema. To prevent complication after surgery is necessary to evaluate and resolve all condition that can lead to poor visual acuity or worse.(51)

Figure 56. Toxic anterior segment syndrome

Source 56.https://emedicine.medscape.com/article/1190343-overview 15.07.2022.

Figure 57. Cystoid macular edema

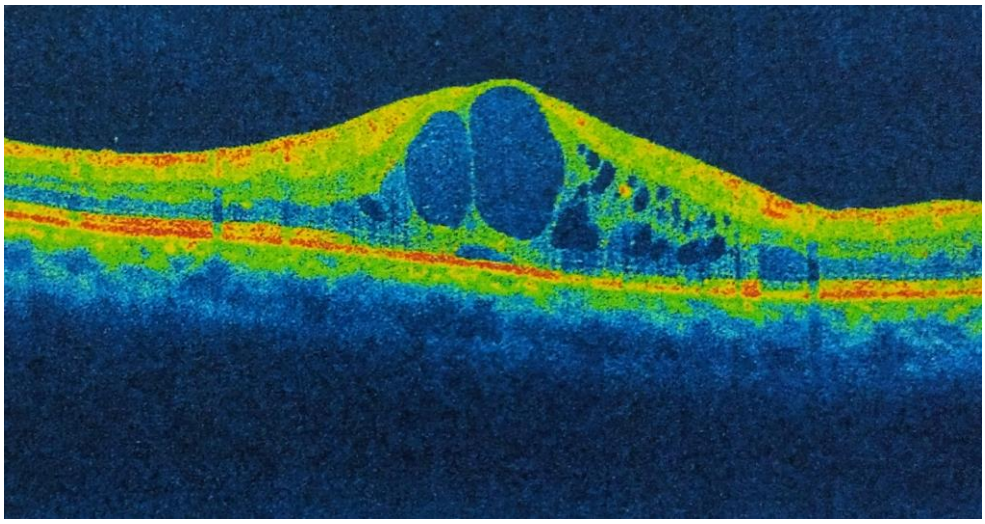

Source 57. https://eyewiki.aao.org/Cystoid_Macular_Edema 15.07.2022.

Figure 58. Dislocated IOL

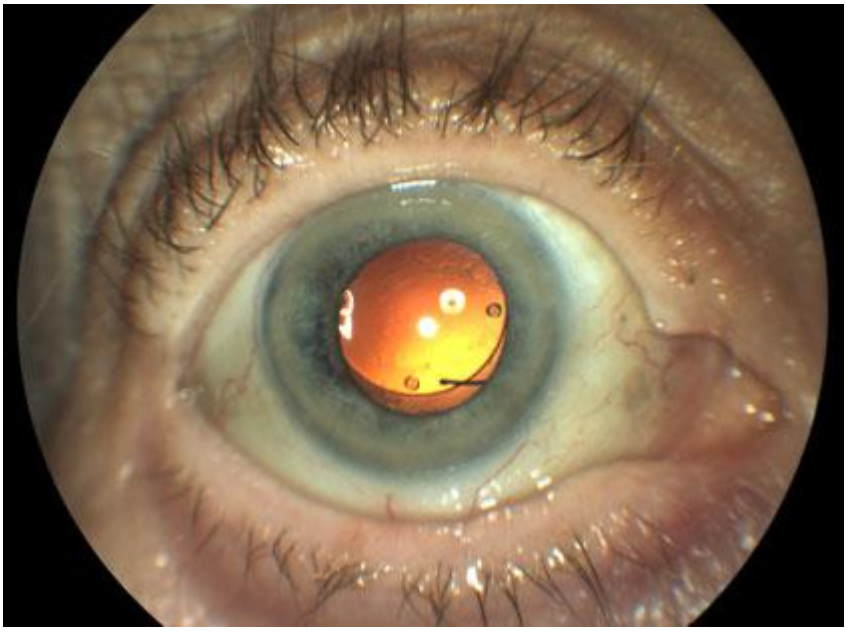

Source 58. https://retinamaculainstitute.com/for-patients/eye-conditions/2018/3/19/dislocated-iol 15.07.2022.

5 Conclusion

Age-related cataract is a common problem in an aging population. Reduced vision due to cataract can greatly affect the patient's ability to perform day activities. Proper care through both nonsurgical and surgical intervention can lead to improved productivity and reduction symptoms corelated to cataract. The optometrist should discuss with the patient the natural course of the cataract and the treatment options, as well as the importance of routine examinations. Cataract patients whose vision acuity is correctable with glasses should be informed that the lens opacities may progress and require other spectacle lens changes or surgery. Patients who cannot otherwise achieve adequate vision acuity for their activities of daily living should be informed that only surgery can help restore their vision acuity. A patient for cataract surgery must be informed of all of the risks and benefits of surgery. The patient should be provided complete information on the pros and cons of the various surgical techniques and types of intraocular lenses. During pre-operative and post-operative examination optometrist need to explain to the patient what expected outcome will be and schedule for postoperative care. The patient who has had cataract surgery should receive proper and timely postoperative care and proper monitoring of ocular health and vision status.

References

1. Hejtmancik JF, Shiels A. Overview of the Lens. Prog Mol Biol Transl Sci [Internet]. 2015 [cited 2022 Jun 10];134:119–27. Available from: https://www.ncbi.nlm.nih.gov/pmc/articles/PMC5656279/

2. Kuszak JR, Zoltoski RK, Sivertson C. Fibre cell organization in crystalline lenses. Exp Eye Res [Internet]. 2004 Mar [cited 2022 Jun 10];78(3):673–87. Available from: https://linkinghub.elsevier.com/retrieve/pii/S0014483503003002

3. Mann IC. The development of the human eye. Oxford, England: Univ. Press; 1928. x, 306 p. (The development of the human eye).

4. Chapter 21 - The Eye1 | Elsevier Enhanced Reader [Internet]. [cited 2022 Jun 12]. Available from: https://reader.elsevier.com/reader/sd/pii/B9780323357753000217?token=81DAB8247C2FD8A8E12F2F20AD95ACCC7180317A295FB480FC924D160E7121B8B36729C7EB91A608E368284A2CADC6E2&originRegion=eu-west-1&originCreation=20220611222718

5. Sang DN. Embryology of the Vitreous. Congenital and Developmental Abnormalities. In: Schepens CL, Neetens A, editors. The Vitreous and Vitreoretinal Interface [Internet]. New York, NY: Springer; 1987 [cited 2022 Jun 7]. p. 11–35. Available from: https://doi.org/10.1007/978-1-4757-1901-7_2

6. Jones HE. HYALOID REMNANTS IN THE EYES OF PREMATURE BABIES. Br J Ophthalmol [Internet]. 1963 Jan 1 [cited 2022 Jun 11];47(1):39–44. Available from: https://bjo.bmj.com/lookup/doi/10.1136/bjo.47.1.39

7. Goldberg MF. Persistent Fetal Vasculature (PFV): An Integrated Interpretation of Signs and Symptoms Associated With Persistent Hyperplastic Primary Vitreous (PHPV) LIV Edward Jackson Memorial Lecture. Am J Ophthalmol [Internet]. 1997 Nov [cited 2022 Sep 4];124(5):587–626. Available from: https://linkinghub.elsevier.com/retrieve/pii/S0002939414708992

8. Wright KW, Spiegel PH. Pediatric Ophthalmology and Strabismus. Springer Science & Business Media; 2013. 1091 p.

9. Shastry BS. Persistent hyperplastic primary vitreous: congenital malformation of the eye. Clin Experiment Ophthalmol [Internet]. 2009 [cited 2022 Jun 12];37(9):884–90. Available from: https://onlinelibrary.wiley.com/doi/abs/10.1111/j.1442-9071.2009.02150.x

10. Pollard ZF. Persistent hyperplastic primary vitreous: diagnosis, treatment and results. Trans Am Ophthalmol Soc [Internet]. 1997 [cited 2022 Jun 7];95:487–549. Available from: https://www.ncbi.nlm.nih.gov/pmc/articles/PMC1298374/

11. Taking a closer look at persistent hyperplastic primary vitreous [Internet]. [cited 2022 Jun 13]. Available from: https://www.healio.com/news/ophthalmology/20160823/taking-a-closer-look-at-persistent-hyperplastic-primary-vitreous

12. Jain P, Pattnaik A, Shinde P. An insight on Bergmeister's Papillae. Indian J Ophthalmol. 2022 Jan 7;2:277–8.

13. Ruan X, Liu Z, Luo L, Liu Y. The Structure of the Lens and Its Associations with the Visual Quality. BMJ Open Ophthalmol [Internet]. 2020 Sep [cited 2022 Jun 14];5(1):e000459. Available from: https://bmjophth.bmj.com/lookup/doi/10.1136/bmjophth-2020-000459

14. Histological-view-of-vertebrate-eye-lens-and-lens-fiber-cells-The-lens-nucleus-is_Q320.jpg (320×320) [Internet]. [cited 2022 Jun 11]. Available from: https://www.researchgate.net/profile/Kalidas-Kohale/publication/277156852/figure/fig2/AS:333242495455234@1456462610474/Histological-view-of-vertebrate-eye-lens-and-lens-fiber-cells-The-lens-nucleus-is_Q320.jpg

15. Giblin FJ. Glutathione: a vital lens antioxidant. J Ocul Pharmacol Ther Off J Assoc Ocul Pharmacol Ther. 2000 Apr;16(2):121–35.

16. Khokhar S, Agarwal T, Kumar G, Kushmesh R, Tejwani LK. Lenticular Abnormalities in Children. J Pediatr Ophthalmol Strabismus [Internet]. 2012 Jan [cited 2022 Sep 13];49(1):32–7. Available from: https://journals.healio.com/doi/10.3928/01913913-20110614-01

17. Bavbek T, Ōgūt MS, Kazokoglu H. Congenital lens coloboma and associated pathologies. Doc Ophthalmol [Internet]. 1993 Apr [cited 2022 Sep 14];83(4):313–22. Available from: http://link.springer.com/10.1007/BF01204333

18. Nirankari MS, Maudgal MC. MICROPHAKIA*. Br J Ophthalmol [Internet]. 1959 May [cited 2022 Sep 12];43(5):314–6. Available from: https://www.ncbi.nlm.nih.gov/pmc/articles/PMC509814/

19. Marzin P, Cormier-Daire V, Tsilou E. Weill-Marchesani Syndrome [Internet]. GeneReviews® [Internet]. University of Washington, Seattle; 2020 [cited 2022 Sep 14]. Available from: https://www.ncbi.nlm.nih.gov/books/NBK1114/

20. Ehlers-Danlos syndromes [Internet]. nhs.uk. 2017 [cited 2022 Sep 15]. Available from: https://www.nhs.uk/conditions/ehlers-danlos-syndromes/

21. Chen T, Deng M, Zhang M, Chen J, Chen Z, Jiang Y. Visual outcomes of lens subluxation surgery with Cionni modified capsular tension rings in Marfan syndrome. Sci Rep [Internet]. 2021 Dec [cited 2022 Sep 14];11(1):2994. Available from: http://www.nature.com/articles/s41598-021-82586-6

22. Hejtmancik JF, Shiels A. Overview of the Lens. Prog Mol Biol Transl Sci [Internet]. 2015 [cited 2022 Jun 10];134:119–27. Available from: https://www.ncbi.nlm.nih.gov/pmc/articles/PMC5656279/

23. Zhang X, Fang J, Hu Y, Xu Y, Higashita R, Liu J. Machine Learning for Cataract Classification and Grading on Ophthalmic Imaging Modalities: A Survey. 2020.

24. Shiels A, Hejtmancik JF. Mutations and mechanisms in congenital and age-related cataracts. Exp Eye Res [Internet]. 2017 Mar 1 [cited 2022 Jun 10];156:95–102. Available from: https://www.sciencedirect.com/science/article/pii/S0014483516301592

25. Jinagal J, Gupta G, Thattaruthody F. Sutural cataract. Indian J Ophthalmol [Internet]. 2018 Jun [cited 2022 Sep 16];66(6):853. Available from: https://www.ncbi.nlm.nih.gov/pmc/articles/PMC5989515/

26. Ionides A. A locus for autosomal dominant posterior polar cataract on chromosome 1p. Hum Mol Genet [Internet]. 1997 Jan 1 [cited 2022 Sep 17];6(1):47–51. Available from: https://academic.oup.com/hmg/article-lookup/doi/10.1093/hmg/6.1.47

27. Vasavada AR, Raj SM, Vasavada V, Shrivastav S. Surgical approaches to posterior polar cataract: a review. Eye [Internet]. 2012 Jun [cited 2022 Sep 17];26(6):761–70. Available from: http://www.nature.com/articles/eye201233

28. Khokhar SK, Pillay G, Dhull C, Agarwal E, Mahabir M, Aggarwal P. Pediatric cataract. Indian J Ophthalmol [Internet]. 2017 Dec [cited 2022 Jun 10];65(12):1340–9. Available from: https://journals.lww.com/ijo/Fulltext/2017/65120/Pediatric_cataract.13.aspx

29. Wormstone IM, Wang L, Liu CSC. Posterior capsule opacification. Exp Eye Res [Internet]. 2009 Feb [cited 2022 Jun 26];88(2):257–69. Available from: https://linkinghub.elsevier.com/retrieve/pii/S0014483508003564

30. Cataracts by Type, Location and Origin [Internet]. Verywell Health. [cited 2022 Sep 17]. Available from: https://www.verywellhealth.com/types-of-cataracts-3421562

31. Kiziltoprak H, Tekin K, Inanc M, Goker YS. Cataract in diabetes mellitus. World J Diabetes [Internet]. 2019 Mar 15 [cited 2022 Sep 17];10(3):140–53. Available from: https://www.ncbi.nlm.nih.gov/pmc/articles/PMC6422859/

32. Bair B, Dodd J, Heidelberg K, Krach K. Cataracts in Atopic Dermatitis: A Case Presentation and Review of the Literature. Arch Dermatol [Internet]. 2011 May 16 [cited 2022 Sep 17];147(5):585–8. Available from: https://doi.org/10.1001/archdermatol.2010.411

33. Ragge NK, Baser ME, Riccardi VM, Falk RE. The ocular presentation of neurofibromatosis 2. Eye [Internet]. 1997 Jan [cited 2022 Sep 17];11(1):12–8. Available from: http://www.nature.com/articles/eye19973

34. Rodriguez-Garcia A, Foster CS. Cataract Surgery in Patients with Uveitis: Preoperative and Surgical Considerations [Internet]. Difficulties in Cataract Surgery. IntechOpen; 2017 [cited 2022 Sep 17]. Available from: https://www.intechopen.com/chapters/undefined/state.item.id

35. Brown NA, Hill AR. Cataract: the relation between myopia and cataract morphology. Br J Ophthalmol [Internet]. 1987 Jun 1 [cited 2022 Sep 17];71(6):405–14. Available from: https://bjo.bmj.com/lookup/doi/10.1136/bjo.71.6.405

36. Themes UFO. Hereditary fundus dystrophies [Internet]. Ento Key. 2019 [cited 2022 Sep 17]. Available from: https://entokey.com/hereditary-fundus-dystrophies-2/

37. Themes UFO. Cataracts and Glaucoma [Internet]. Ento Key. 2016 [cited 2022 Sep 17]. Available from: https://entokey.com/cataracts-and-glaucoma/

38. Frampton G, Harris P, Cooper K, Lotery A, Shepherd J. Background [Internet]. The clinical effectiveness and cost-effectiveness of second-eye cataract surgery: a systematic review and economic evaluation. NIHR Journals Library; 2014 [cited 2022 Sep 17]. Available from: https://www.ncbi.nlm.nih.gov/books/NBK263908/

39. Effective Ocular Biometry and Intraocular Lens Power Calculation. Eur Ophthalmic Rev [Internet]. 2017 Jan 23 [cited 2022 Oct 16]; Available from: https://www.touchophthalmology.com/anterior-segment/journal-articles/effective-ocular-biometry-and-intraocular-lens-power-calculation/

40. Frings A, Dulz S, Skevas C, Stemplewitz B, Linke SJ, Richard G, et al. Postoperative refractive error after phacovitrectomy for epiretinal membrane with and without macular oedema. Graefes Arch Clin Exp Ophthalmol [Internet]. 2015 Jul 1 [cited 2022 Oct 16];253(7):1097–104. Available from: https://doi.org/10.1007/s00417-015-2948-8

41. Sahin A, Hamrah P. Clinically relevant biometry. Curr Opin Ophthalmol [Internet]. 2012 Jan [cited 2022 Oct 16];23(1):47–53. Available from: https://journals.lww.com/00055735-201201000-00010

42. An Ophthalmic Success Story: The History of IOL Materials [Internet]. CRSTEurope. [cited 2022 Oct 22]. Available from: https://crstodayeurope.com/articles/2006-sep/0906_18-php/

43. Maedel S, Evans JR, Harrer-Seely A, Findl O. Intraocular lens optic edge design for the prevention of posterior capsule opacification after cataract surgery. Cochrane Database Syst Rev [Internet]. 2021 Aug 16 [cited 2022 Oct 22];2021(8):CD012516. Available from: https://www.ncbi.nlm.nih.gov/pmc/articles/PMC8406949/

44. Yamauchi T, Tabuchi H, Takase K, Ohsugi H, Ohara Z, Kiuchi Y. Comparison of Visual Performance of Multifocal Intraocular Lenses with Same Material Monofocal Intraocular Lenses. PLOS ONE [Internet]. 2013 Jun 28 [cited 2022 Oct 17];8(6):e68236. Available from: https://journals.plos.org/plosone/article?id=10.1371/journal.pone.0068236

45. Nowik KE, Nowik K, Kanclerz P, Szaflik JP. Clinical Performance of Extended Depth of Focus (EDOF) Intraocular Lenses – A Retrospective Comparative Study of Mini Well Ready and Symfony. Clin Ophthalmol [Internet]. 2022 May [cited 2022 Oct 22];Volume 16:1613–21. Available from: https://www.dovepress.com/clinical-performance-of-extended-depth-of-focus-edof-intraocular-lense-peer-reviewed-fulltext-article-OPTH

46. Simões PS, Ferreira TB. Iris-Fixated Intraocular Lenses for Ametropia and Aphakia. Med Hypothesis Discov Innov Ophthalmol [Internet]. 2014 [cited 2022 Oct 22];3(4):116–22. Available from: https://www.ncbi.nlm.nih.gov/pmc/articles/PMC4352205/

47. Mahapatra SK, Mannem N. Anterior chamber intraocular lens - An effective alternative in traumatic and surgical aphakia in the era of scleral-fixated intraocular lens. Indian J Ophthalmol [Internet]. 2021 Jun [cited 2022 Oct 22];69(6):1404–8. Available from: https://www.ncbi.nlm.nih.gov/pmc/articles/PMC8302310/

48. Ng J, Ophthalmologist, Behshad S, Ophthalmologist, Farid M, Director of Cornea, Cataract, and Refractive Surgery and Vice-Chair of Ophthalmic Faculty, University of California-Irvine, Gavin Herbert Eye Institute, Irvine, California, US. Review of Surgical Techniques for Posterior Chamber Intraocular Lens Fixation in the Absence of Capsular Lens Support. US Ophthalmic Rev [Internet]. 2015 [cited 2022 Oct 23];08(02):86. Available from: http://www.touchophthalmology.com/articles/review-surgical-techniques-posterior-chamber-intraocular-lens-fixation-absence-capsular

49. Intracapsular Cataract Extraction - an overview | ScienceDirect Topics [Internet]. [cited 2022 Jun 25]. Available from: https://www.sciencedirect.com/topics/nursing-and-health-professions/intracapsular-cataract-extraction

50. Gavris MM, Belicioiu R, Olteanu I, Horge I. THE ADVANTAGES OF FEMTOSECOND LASER-ASSISTED CATARACT SURGERY. Romanian J Ophthalmol [Internet]. 2015 [cited 2022 Oct 22];59(1):38–42. Available from: https://www.ncbi.nlm.nih.gov/pmc/articles/PMC5729808/

51. Gaskin GL, Pershing S, Cole TS, Shah NH. Predictive Modeling of Risk Factors and Complications of Cataract Surgery. Eur J Ophthalmol [Internet]. 2016 Jul [cited 2022 Jun 26];26(4):328–37. Available from: http://journals.sagepub.com/doi/10.5301/ejo.5000706

52. Robman L, Taylor H. External factors in the development of cataract. Eye [Internet]. 2005 Oct [cited 2022 May 21];19(10):1074–82. Available from: https://www.nature.com/articles/6701964

53. Francis PJ, Berry V, Bhattacharya SS, Moore AT. The genetics of childhood cataract. J Med Genet [Internet]. 2000 Jul 1 [cited 2022 May 21];37(7):481–8. Available from: https://jmg.bmj.com/content/37/7/481